

ENDOMETRİOZİS ve ADENOMYOZİS DERNEĞİ  
Endoakademi Toplantıları VII  
"Endometrioma Yönetimi 2018"  
01 Nisan 2018, Pazar  
Radisson Blu Hotel, Kayseri



# Nasıl Daha İyi Endometrioma Cerrahisi Yapabiliriz?

**Doç.Dr.Taner USTA**

*Acıbadem Altunizade Hastanesi,  
Kadın Hastalıkları ve Doğum Kliniği,  
Acıbadem Üniversitesi, İstanbul.*



**ACIBADEM**  
ALTUNİZADE

# Objectives

 **Anatominin güvenli exposure'ı için güvenli teknikler**

 **Endometriozis için Cerrahi teknikler**

 **İpuçları & Püf noktaları**

# Standardizasyon mümkün mü?



# Standardizasyon mümkün mü?



# Standardizasyon mümkün mü?



# Controversies in endometriosis and adenomyosis

Liège, Belgium

4-6 December 2014


Incidental findings of peritoneal,  
ovarian and deep endometriosis

Prof TC Li

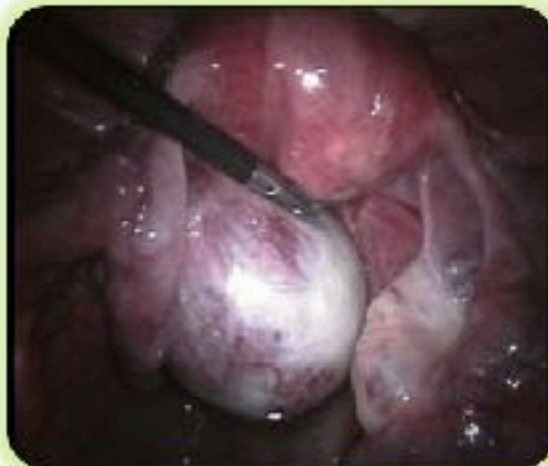Chinese University of Hong Kong



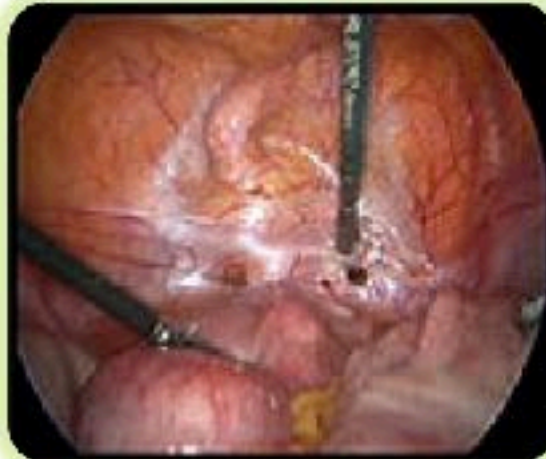# Endometriosis



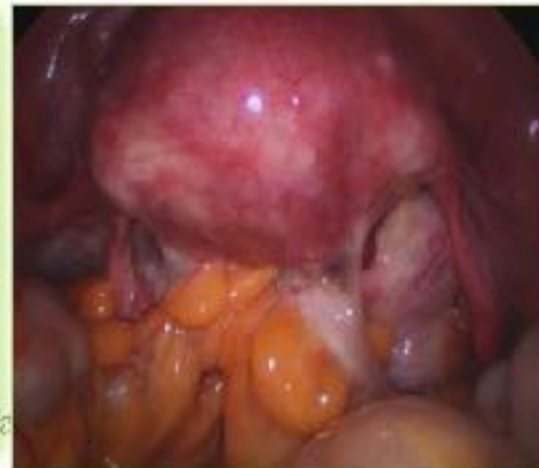**endometrioma**



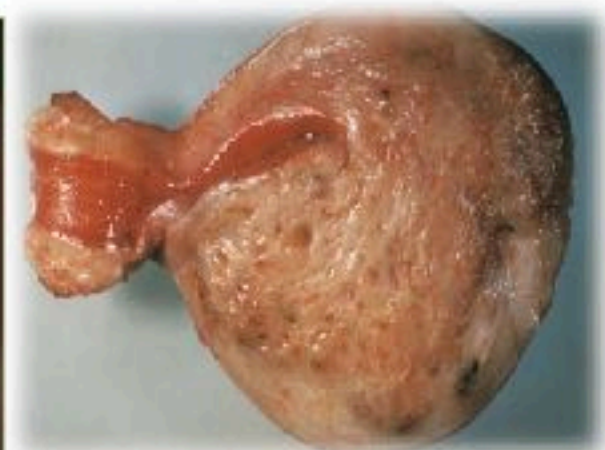**peritoneal  
endometriosis**



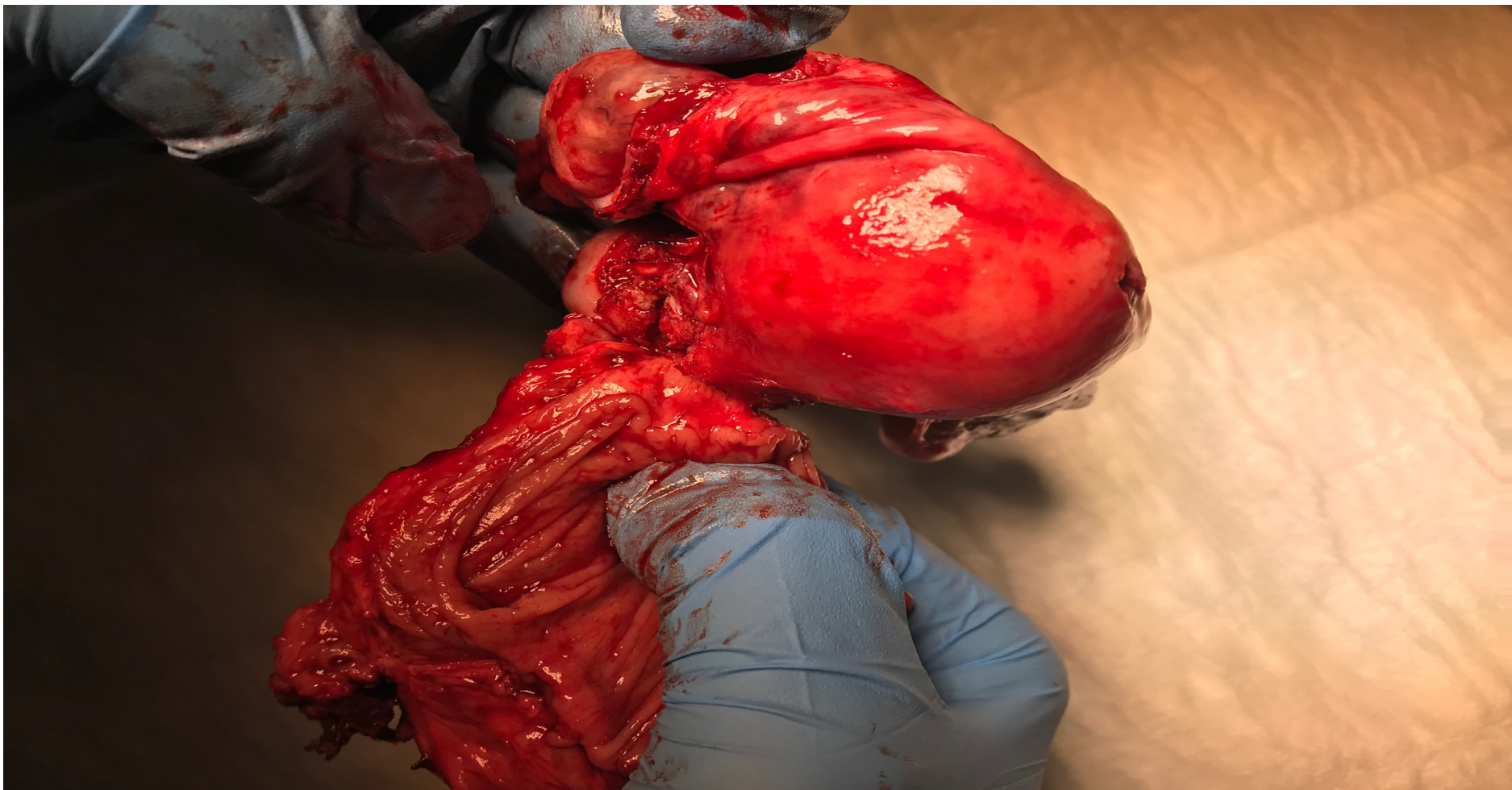
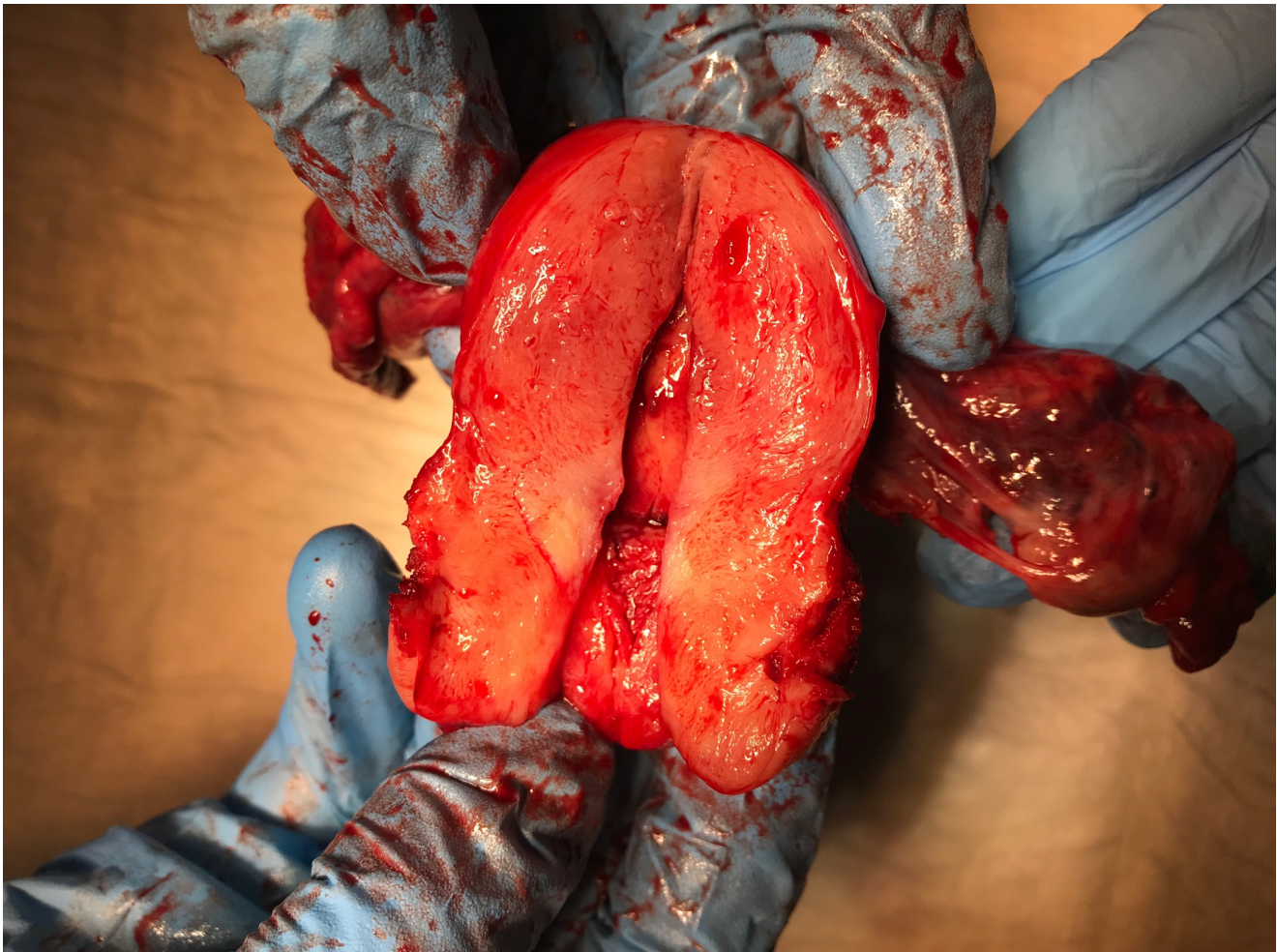
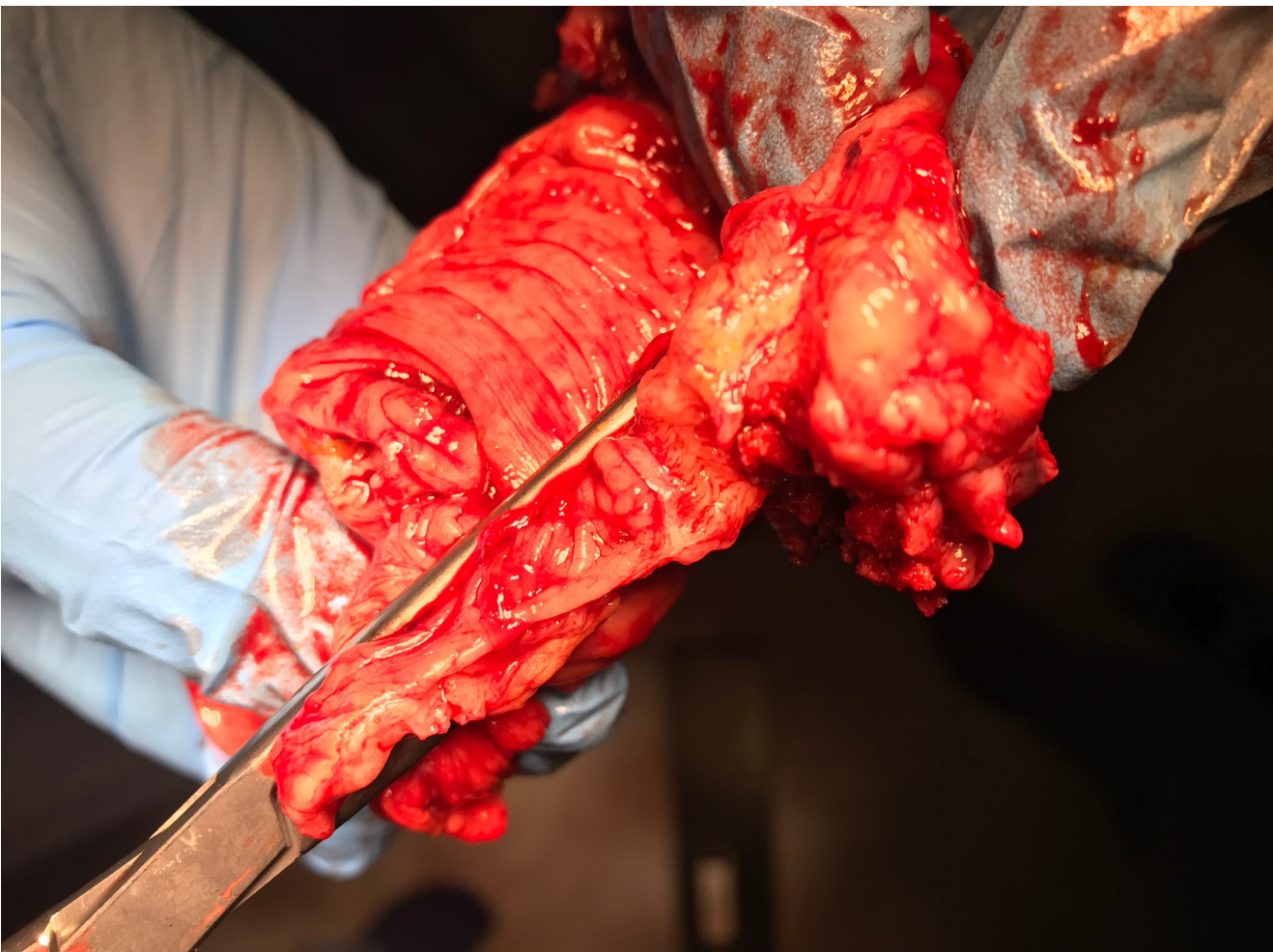
**deep infiltrating  
endometriosis**



**adenomyosis**



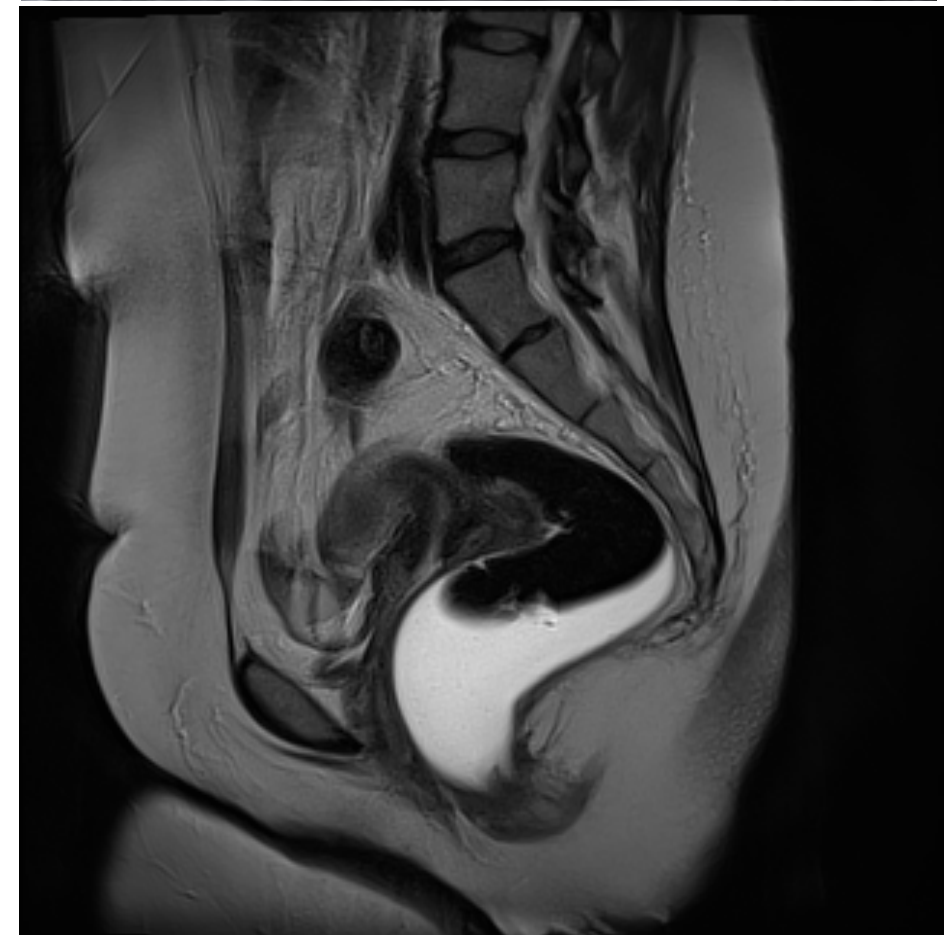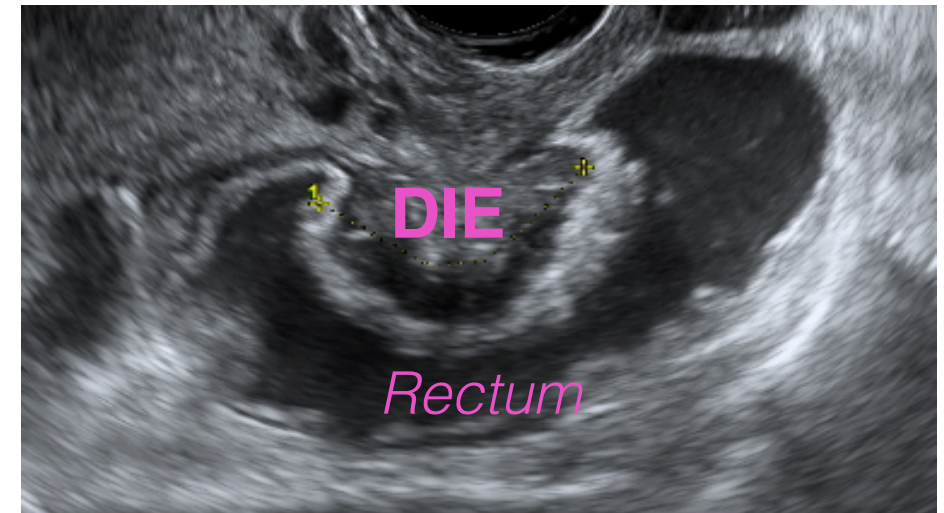

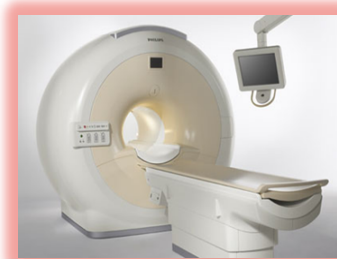
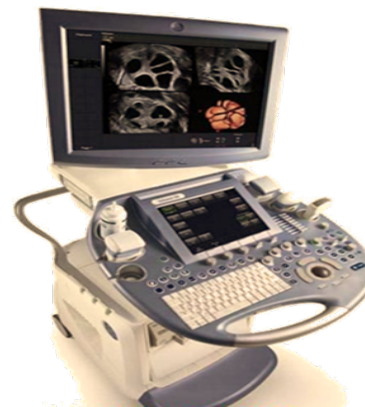



# Tani

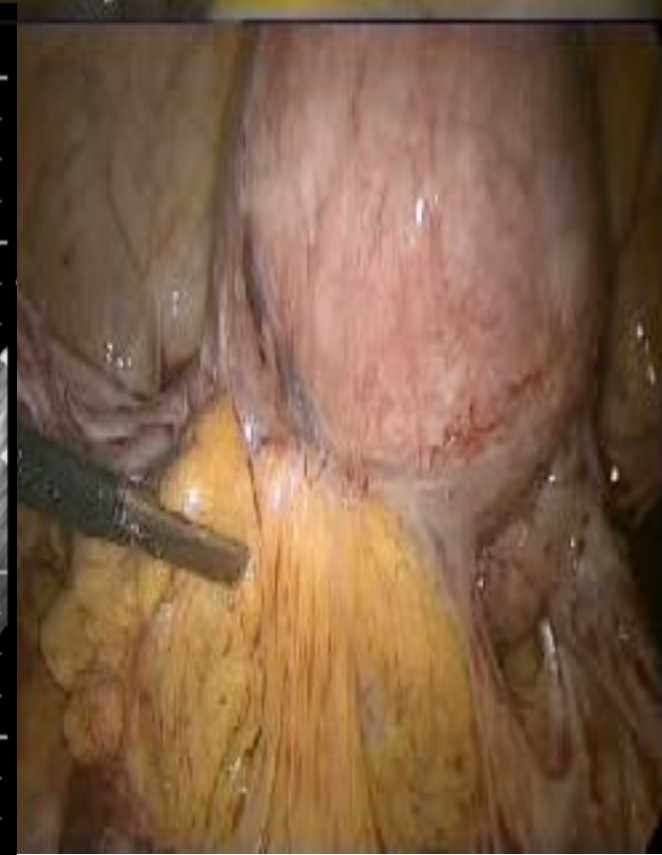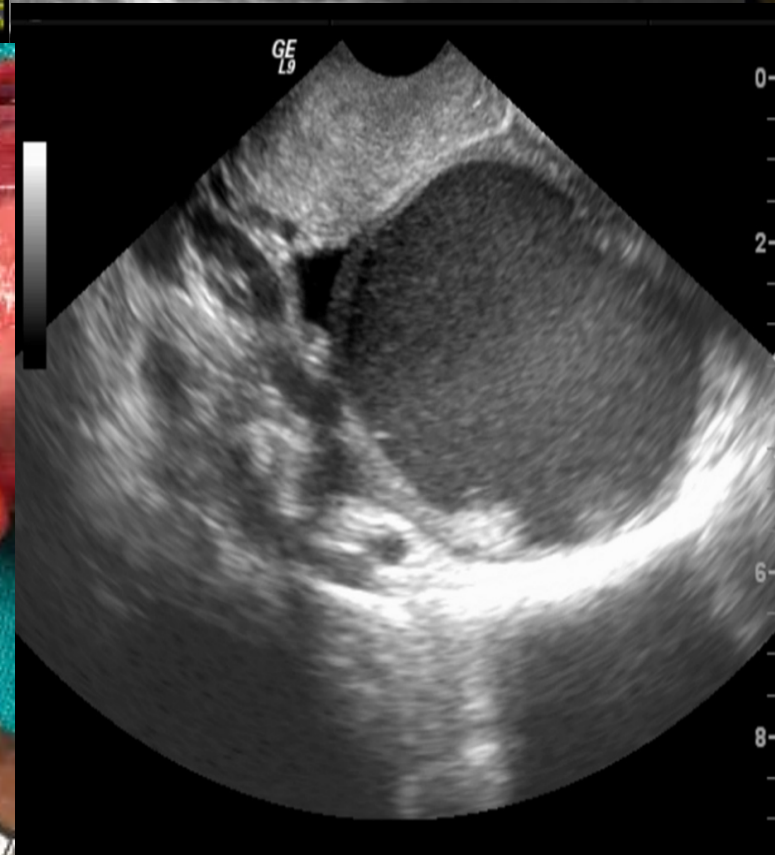
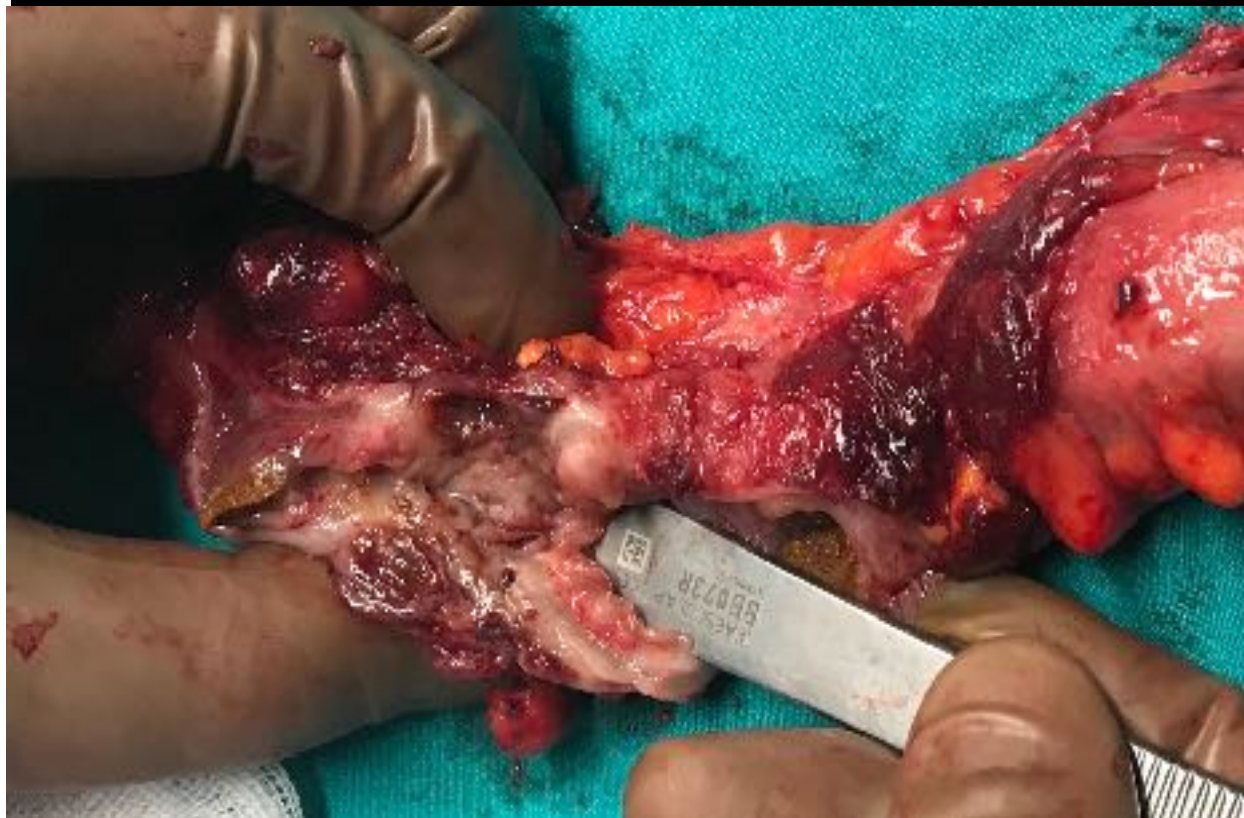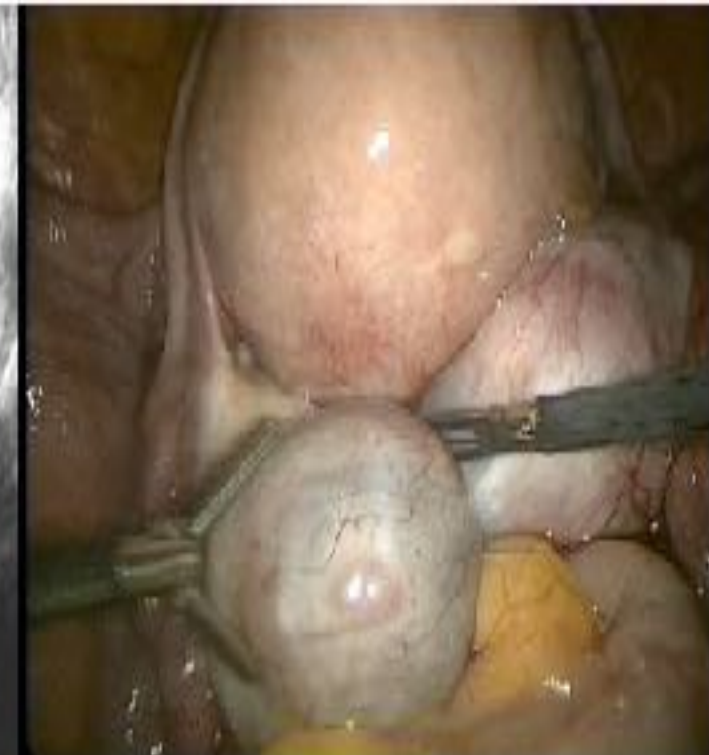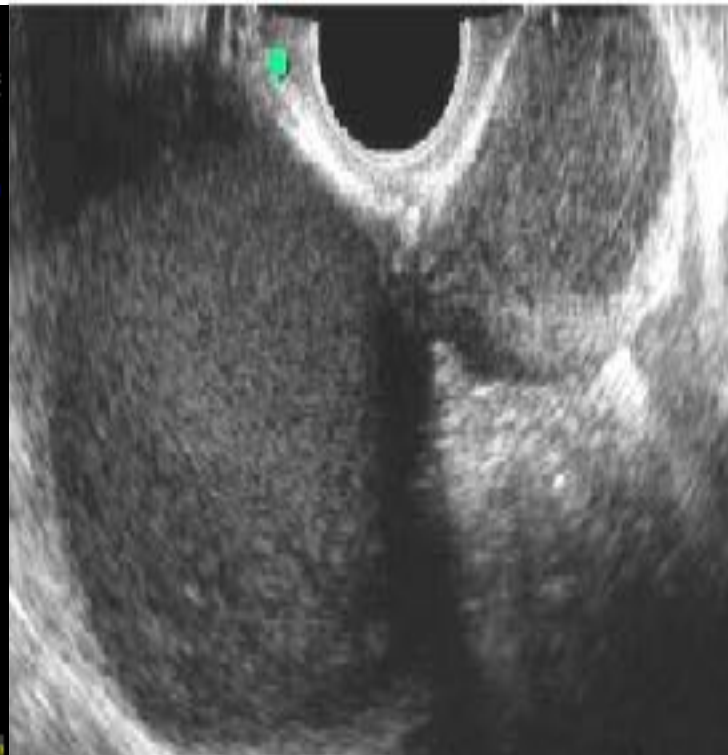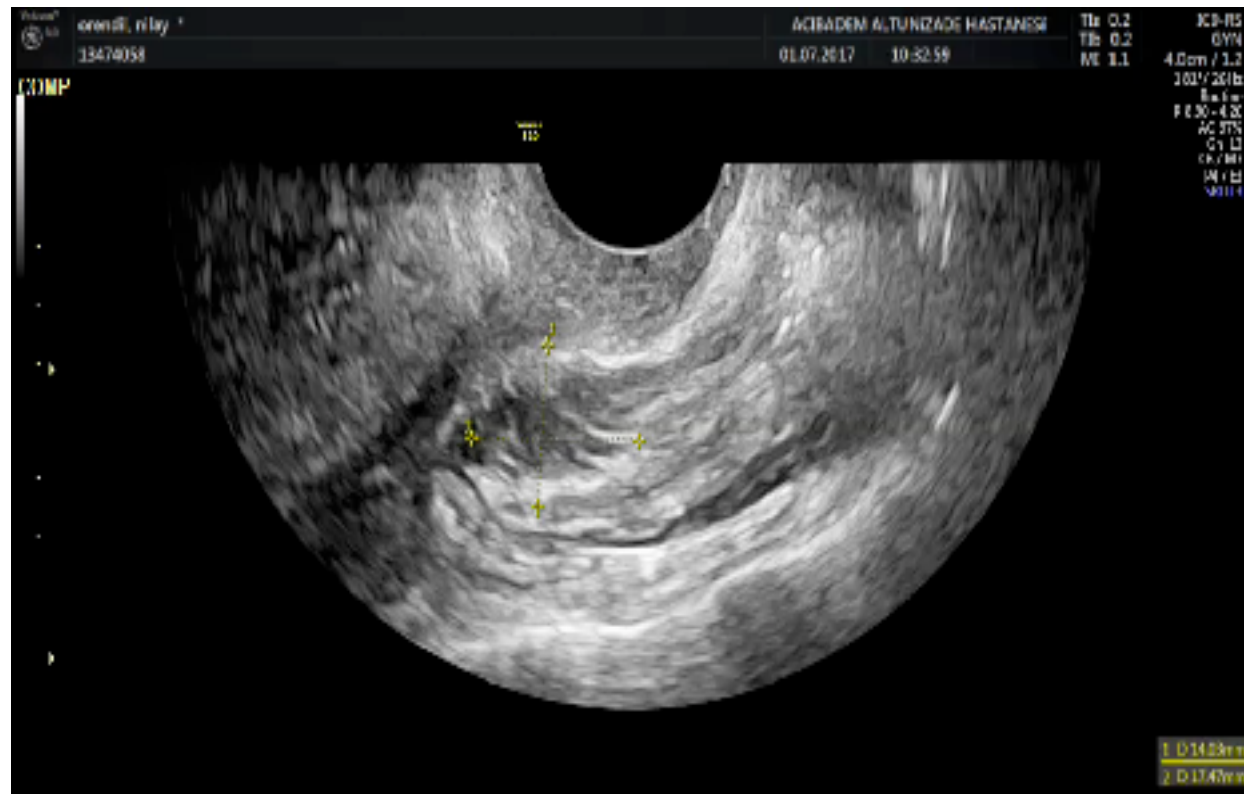
- Klinik Hikaye
- Fizik Muayene
- Ultrasonografi (TR/TV)
- MRI
- Kolonoskopi
- Circulating Micro RNA



*Cosar E, Mamillapalli R, Ersoy GS, Cho S, Seifer B, Taylor HS. Serum microRNAs as diagnostic markers of endometriosis: a comprehensive array-based analysis. Fertil Steril. 2016 Aug;106(2):402-9.*

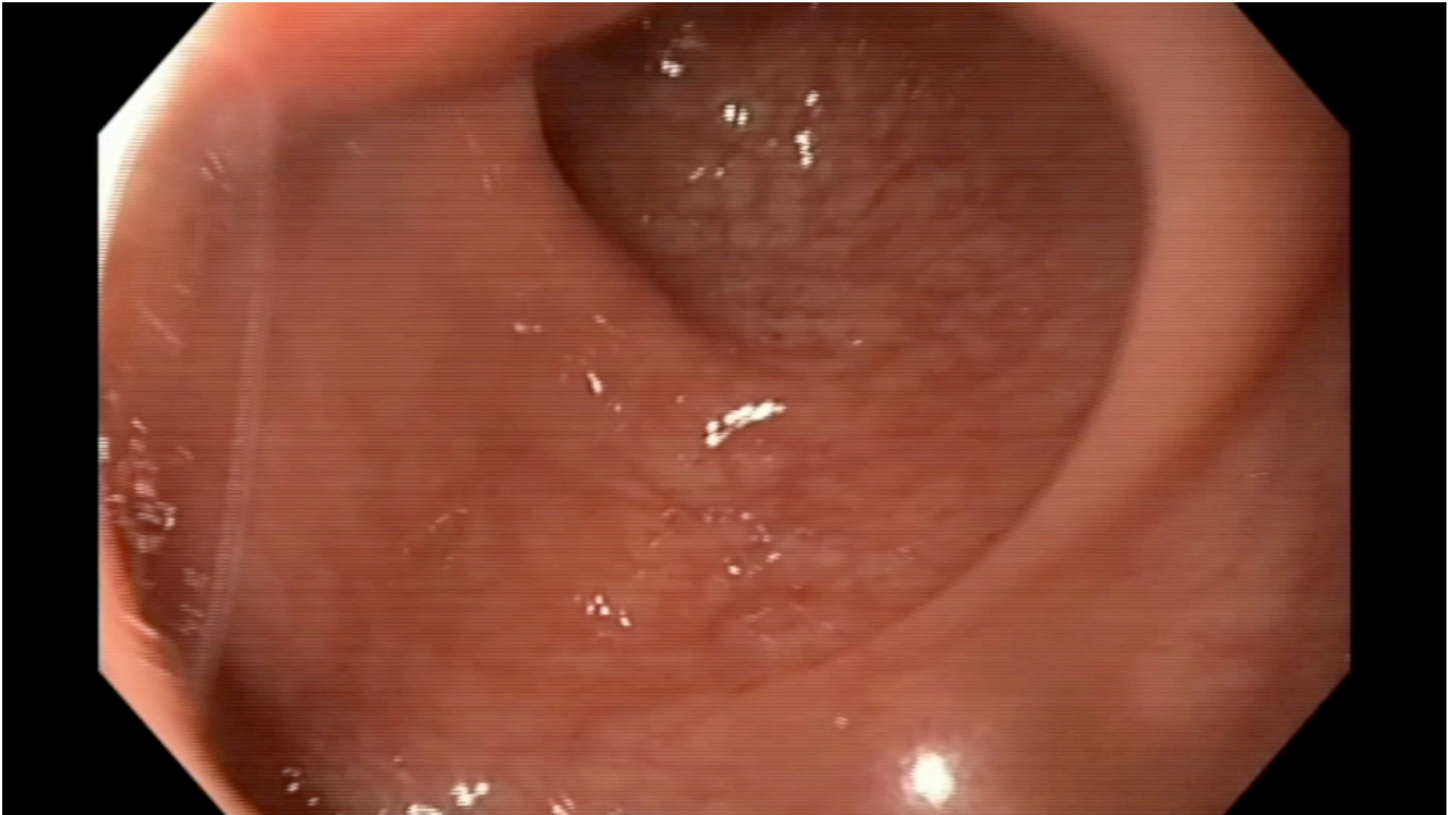

# Preop Planlama / Yol Haritası





# Preop Planlama / Yol Haritası



# The prediction of pouch of Douglas obliteration using offline analysis of the transvaginal ultrasound 'sliding sign' technique: inter- and intra-observer reproducibility

Human Reproduction, Vol.28, No.5 pp. 1237–1246, 2013


S. Reid<sup>1,\*</sup>, C. Lu<sup>2</sup>, I. Casikar<sup>1</sup>, B. Mein<sup>3</sup>, R. Magotti<sup>3</sup>, J. Ludlow<sup>4</sup>,  
R. Benzie<sup>3</sup>, and G. Condous<sup>1</sup>

**STUDY QUESTION:** What is the inter-/intra-observer agreement and diagnostic accuracy among gynaecological and non-gynaecological ultrasound specialists in the prediction of pouch of Douglas (POD) obliteration (secondary to endometriosis) at offline analysis of two-dimensional videos using the dynamic real-time transvaginal ultrasound (TVS) 'sliding sign' technique?

**SUMMARY ANSWER:** The inter-/intra-observer agreement and diagnostic accuracy for the interpretation of the TVS 'sliding sign' in the prediction of POD obliteration was found to be very acceptable, ranging from substantial to almost perfect agreement for the observers who specialized in gynaecological ultrasound.



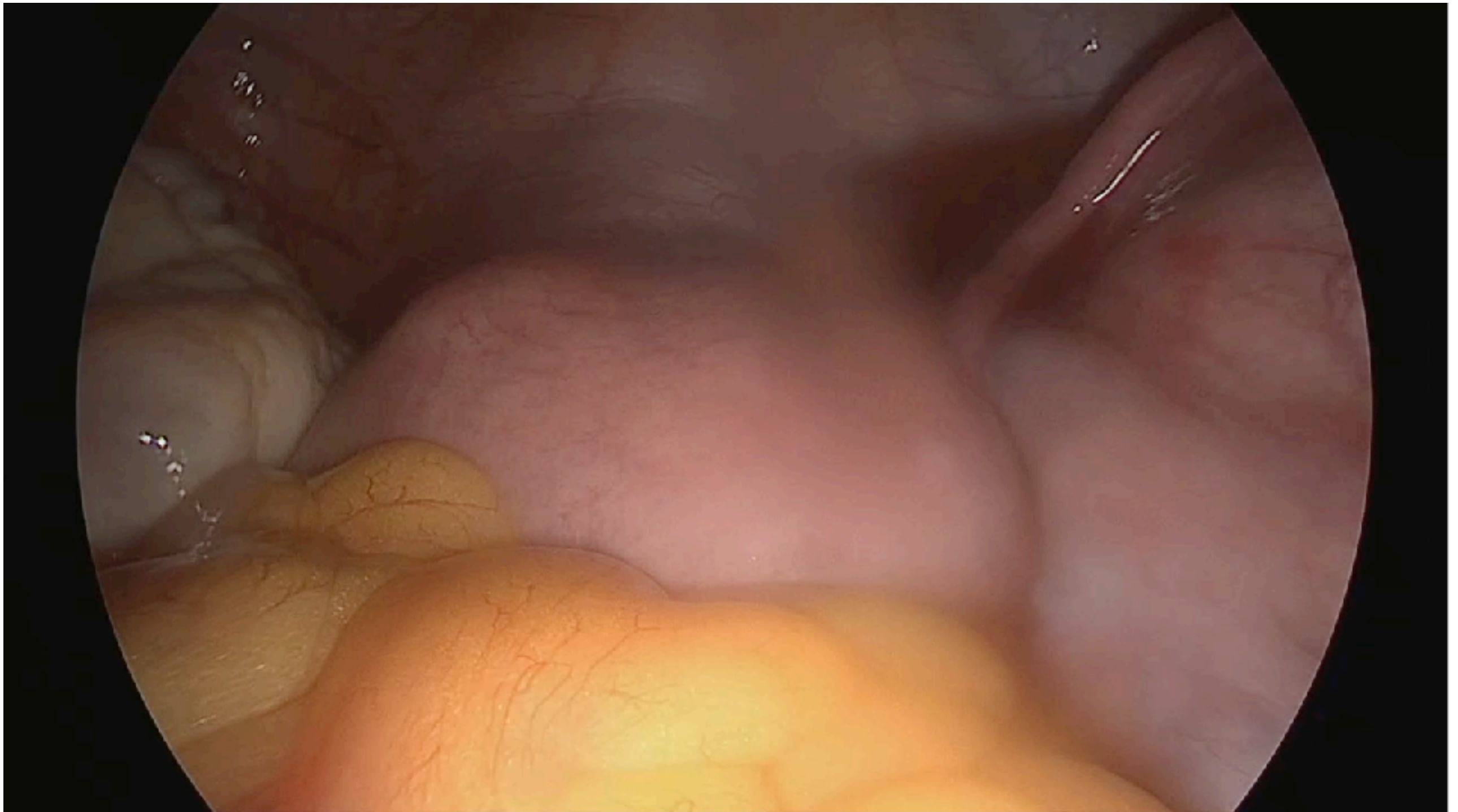
# *Obliterated Pouch Of Douglas*



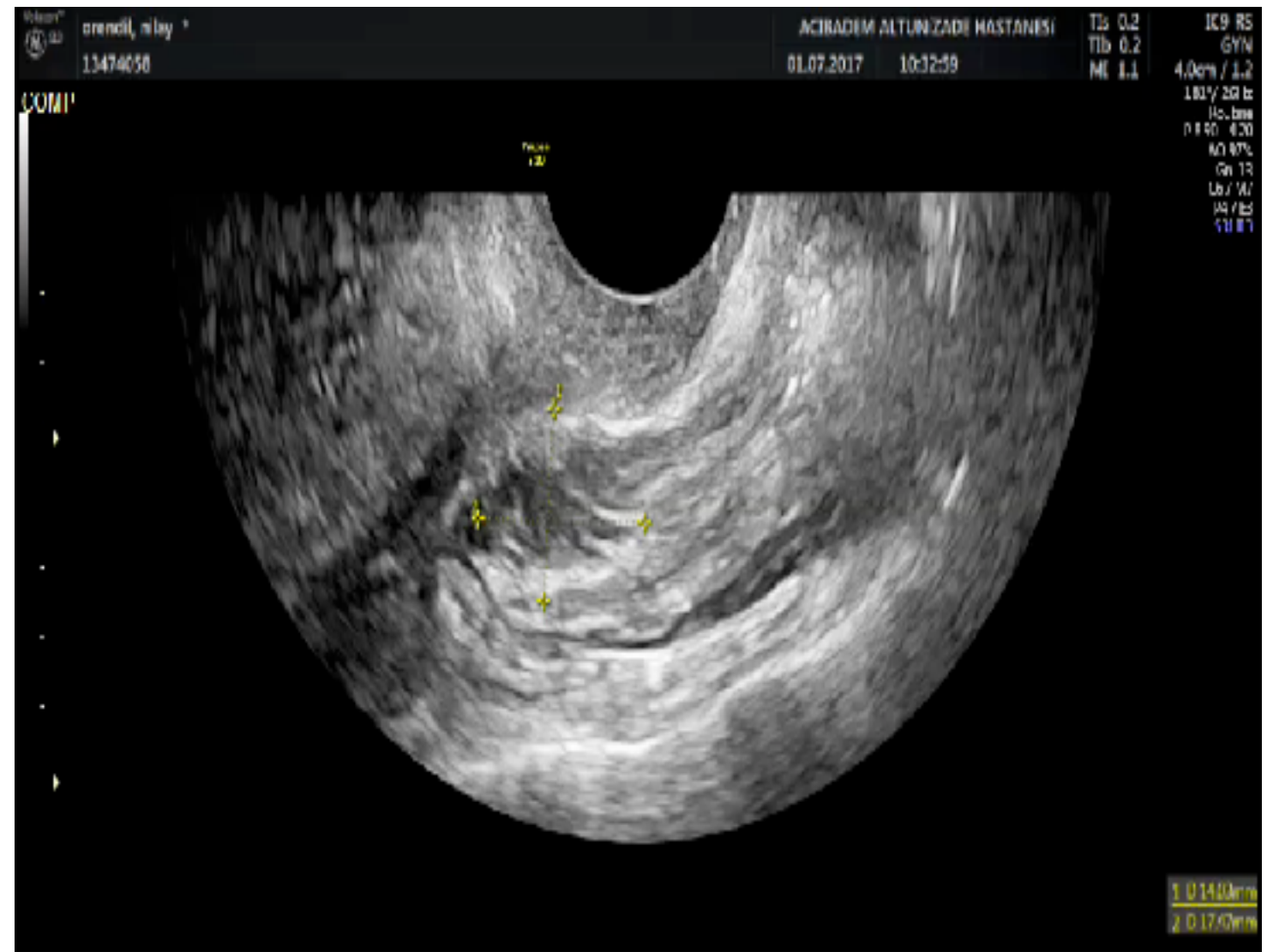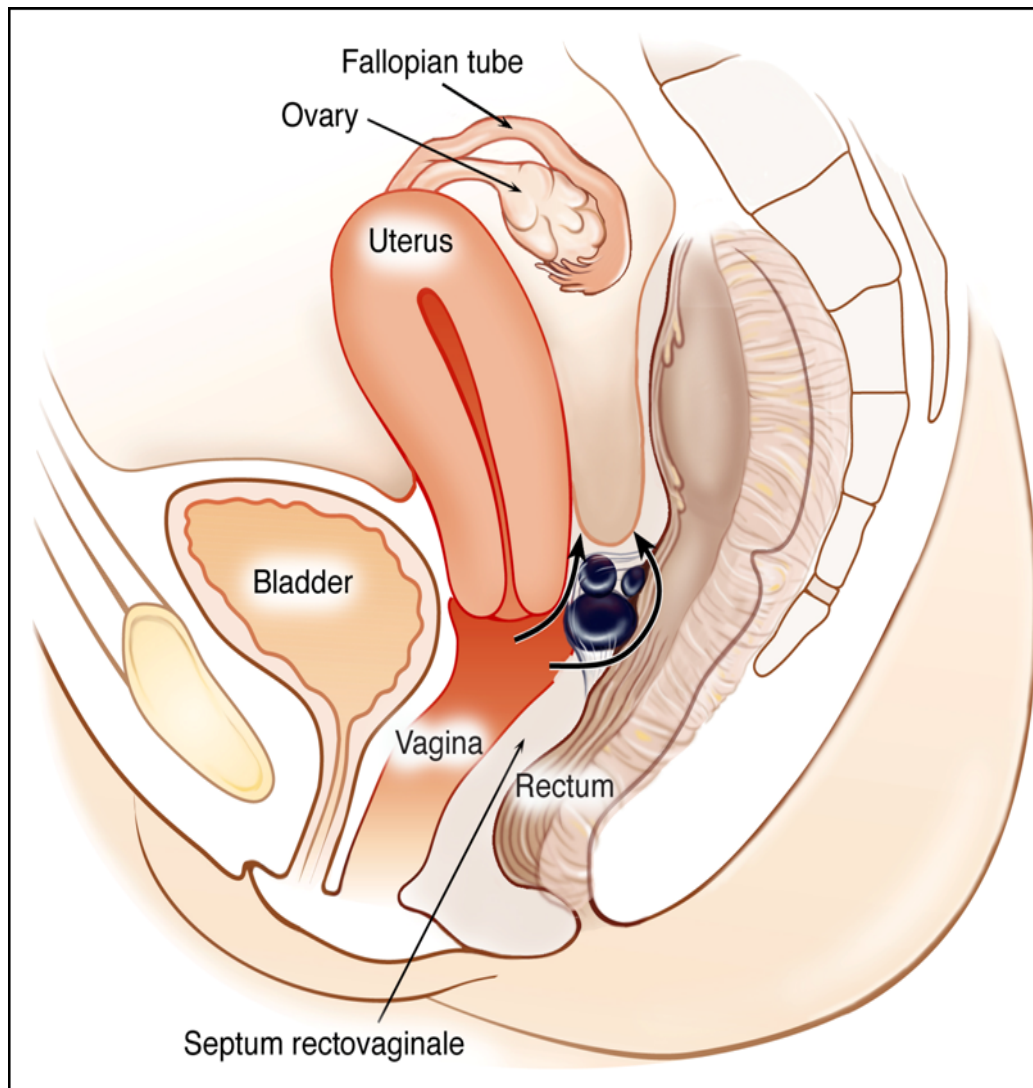
# *Olgu*

- N.Ö., 36, bekar
- Şiddetli Pelvik ağrı, Adet dönemi ağrıları daha da dayanılmaz oluyormuş.
- Hasta ağrı ve çikolata kisti nedeni ile 5 ay önce opere edilmiş.
- Ameliyattan sonra ağrıları 1 ay geçmiş, sonra aynı şiddette tekrarlamış.
- TVUSG'de overler biri küçük (opere edilen), diğeri normal.

*Olgu*

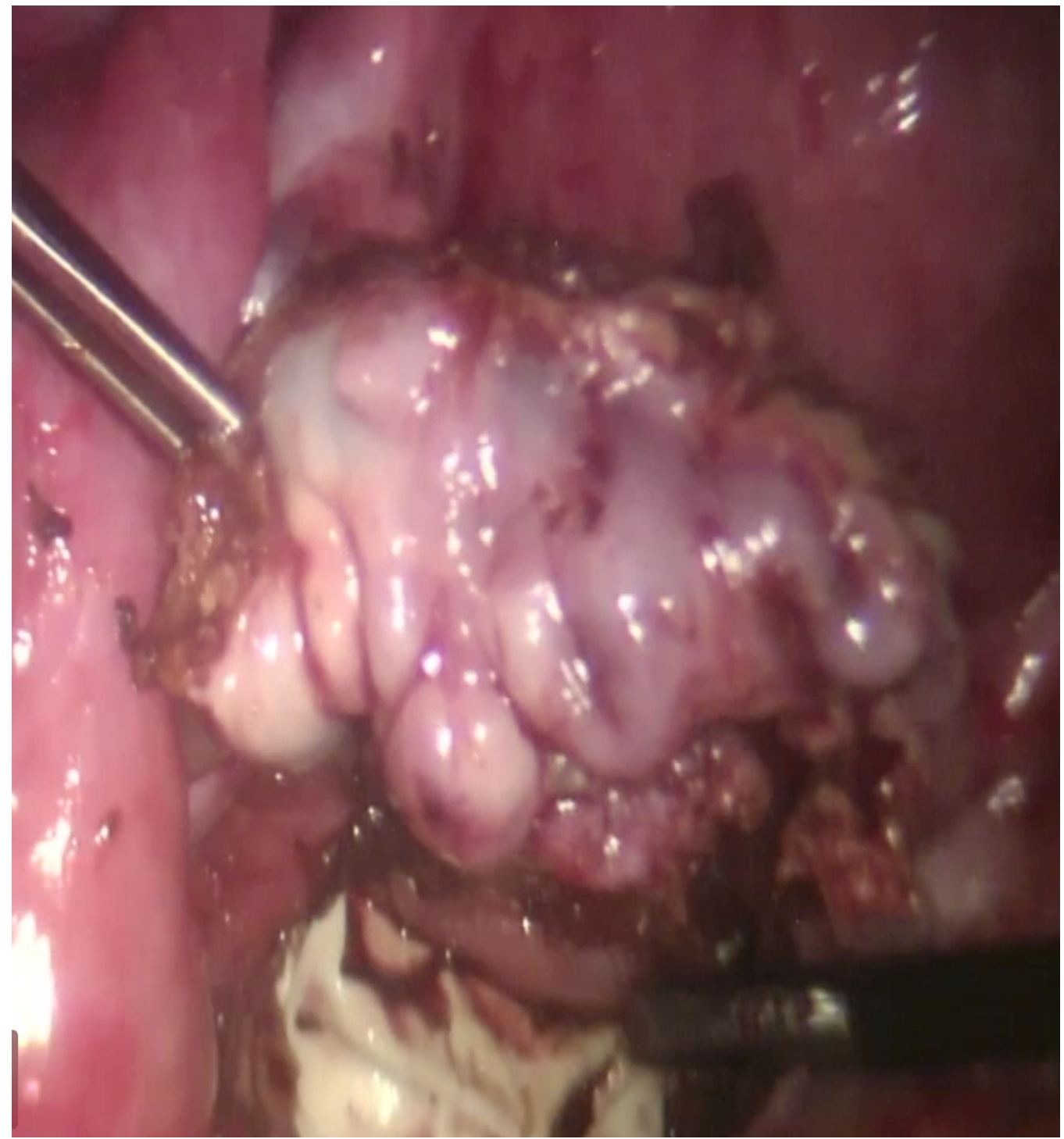
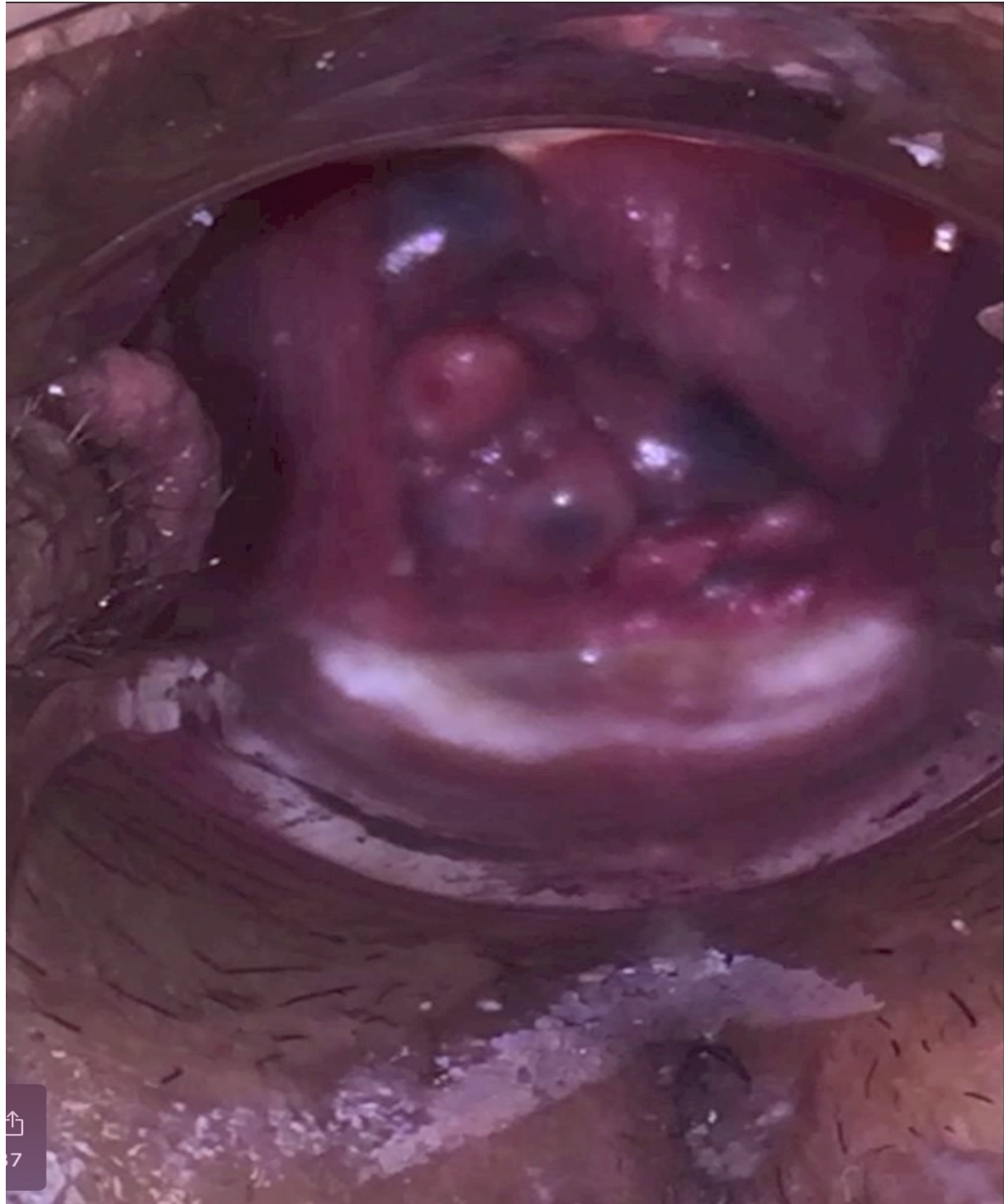
# Olgu





# *Olgu*



# Cerrahi Risk



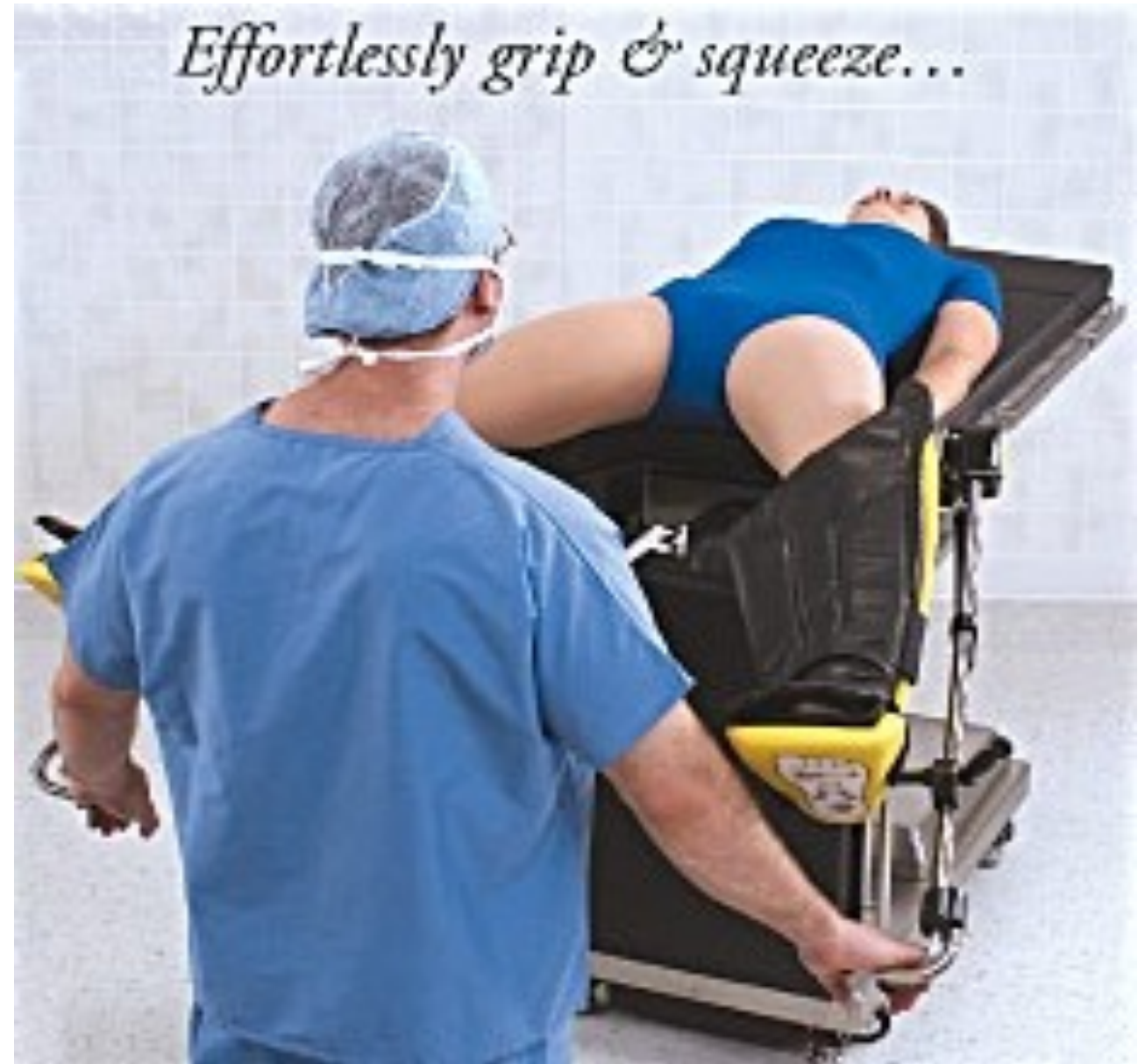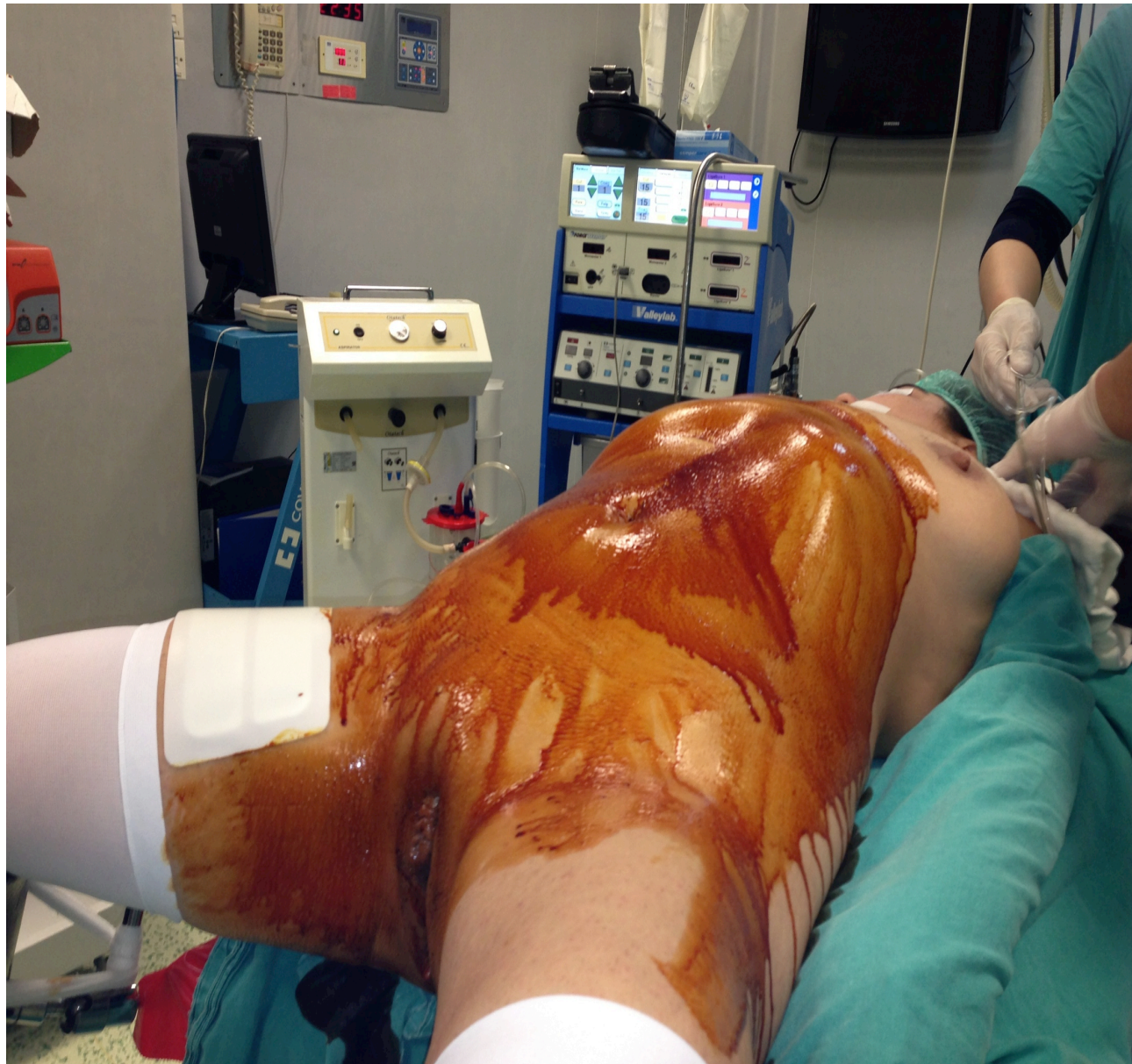- **Normal over korteksinin eksizyonu**



- **Rekürrens**

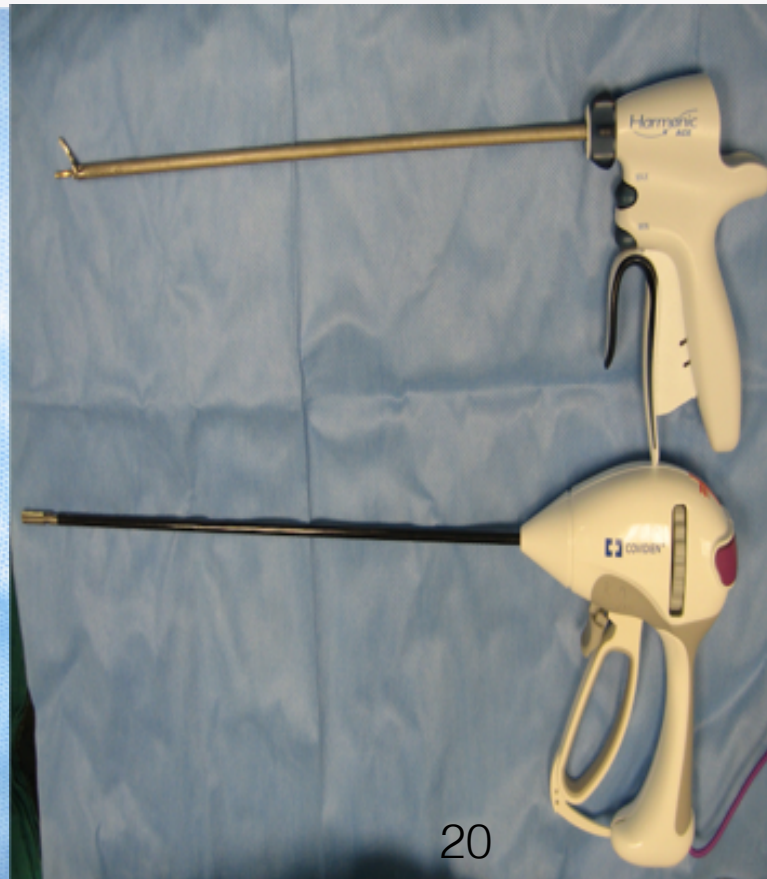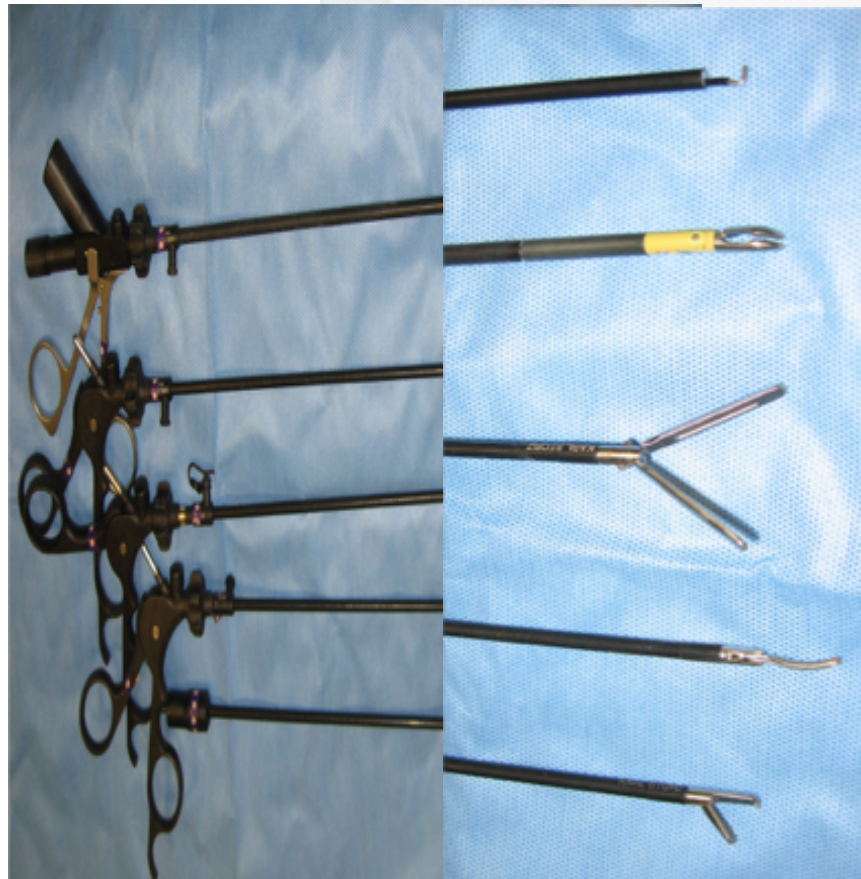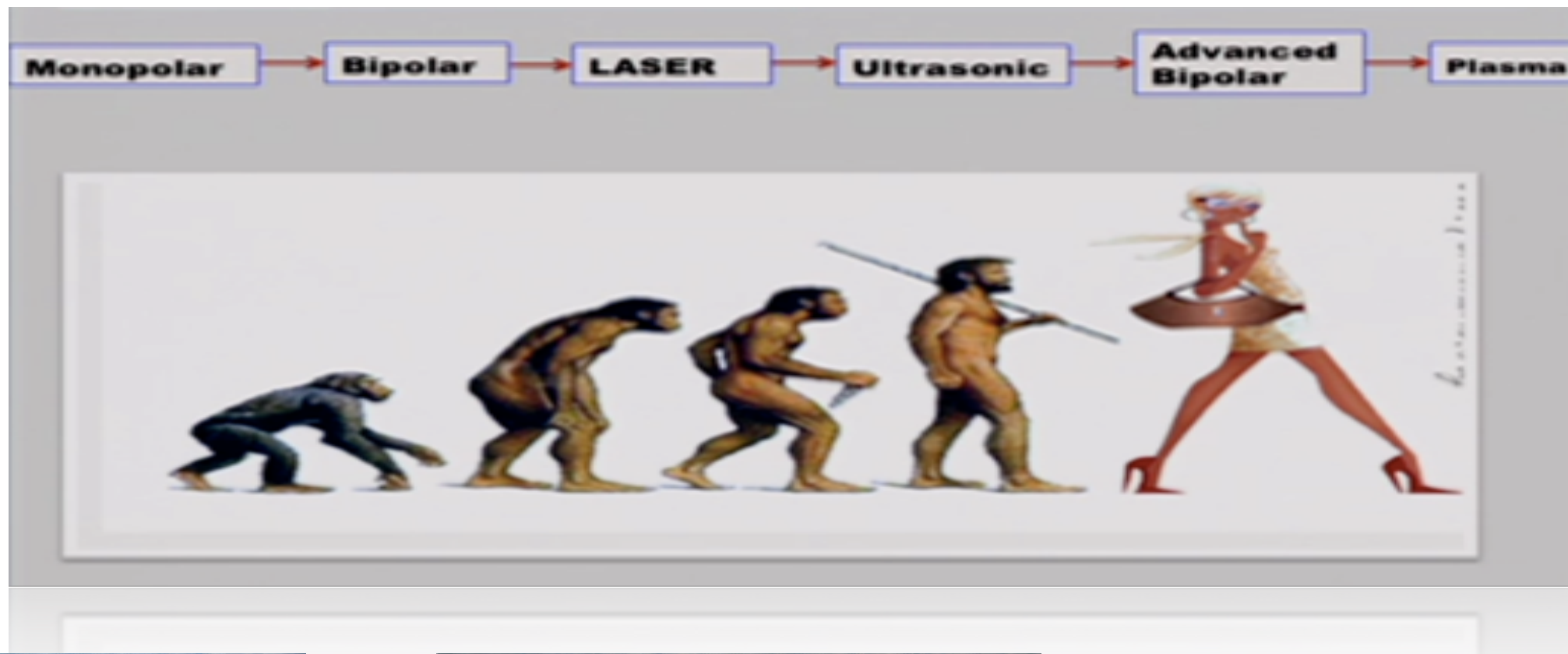


# Hasta Pozisyonu



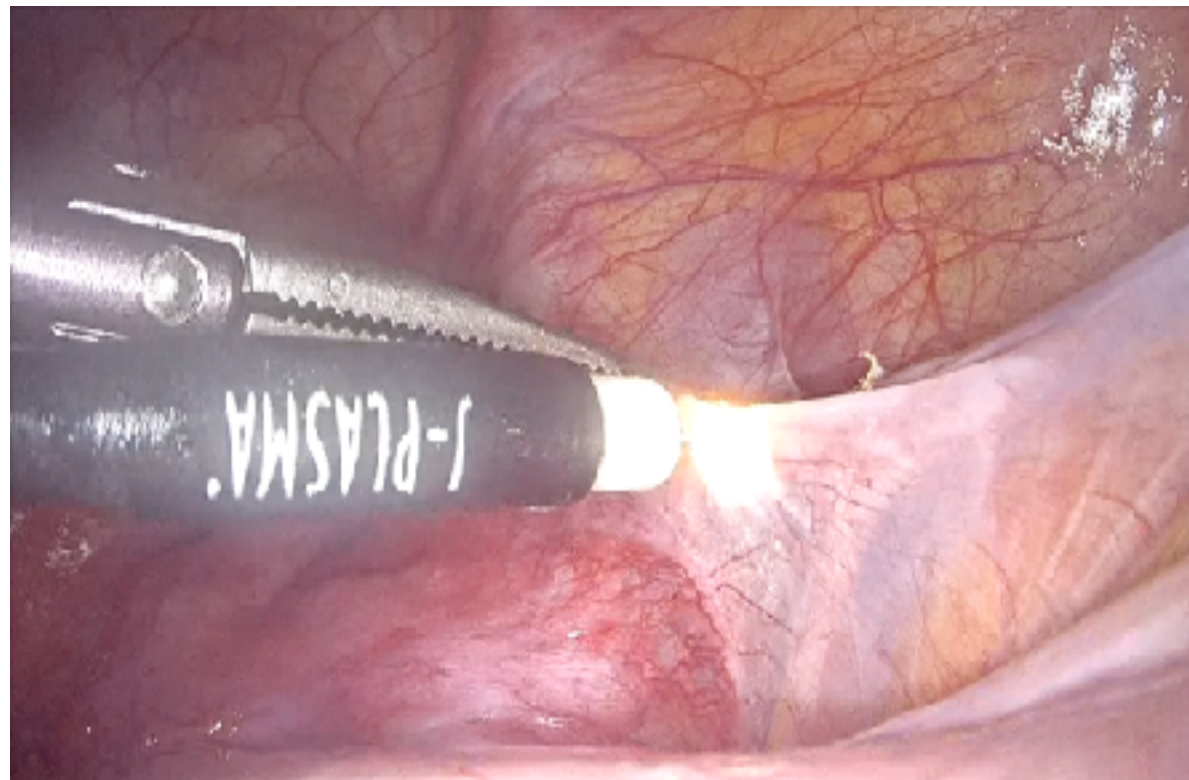
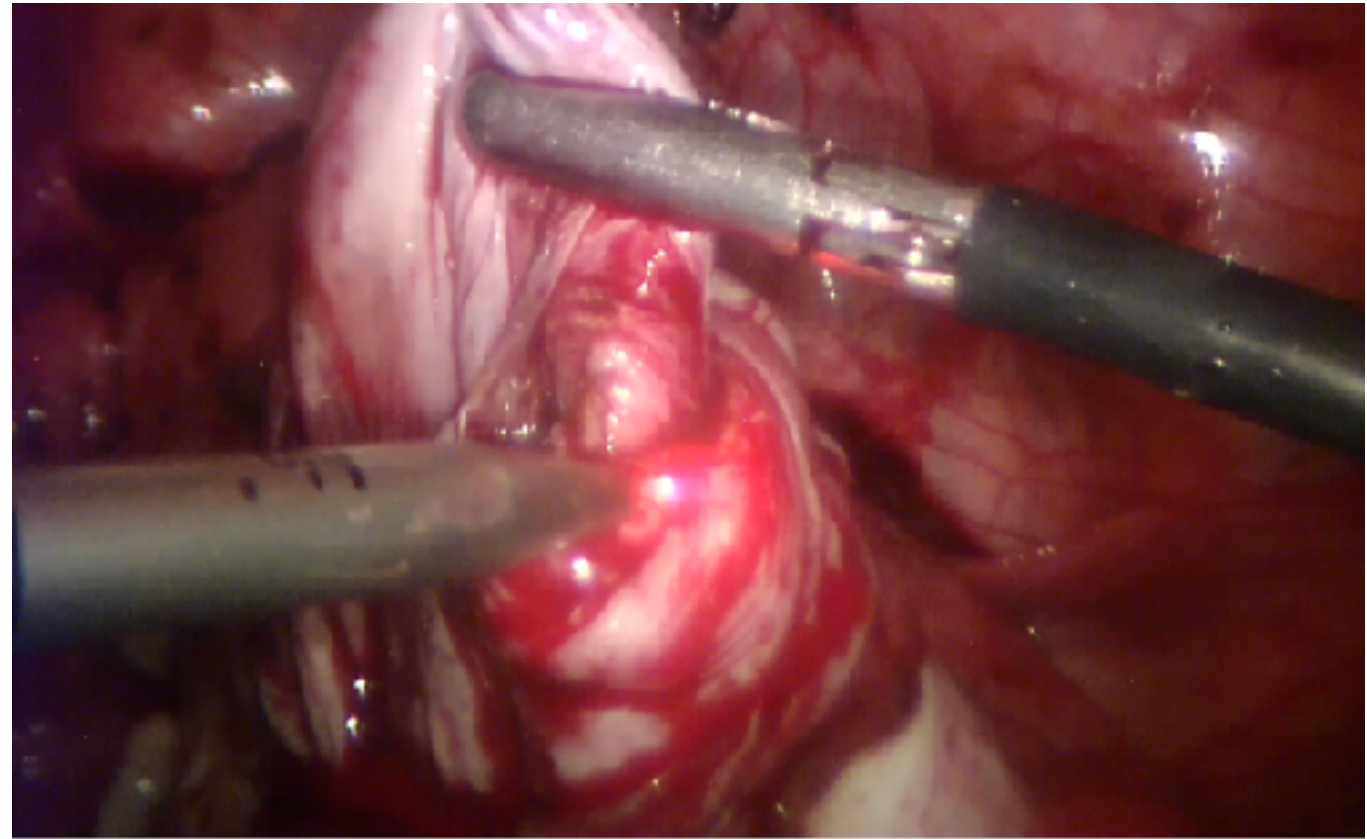
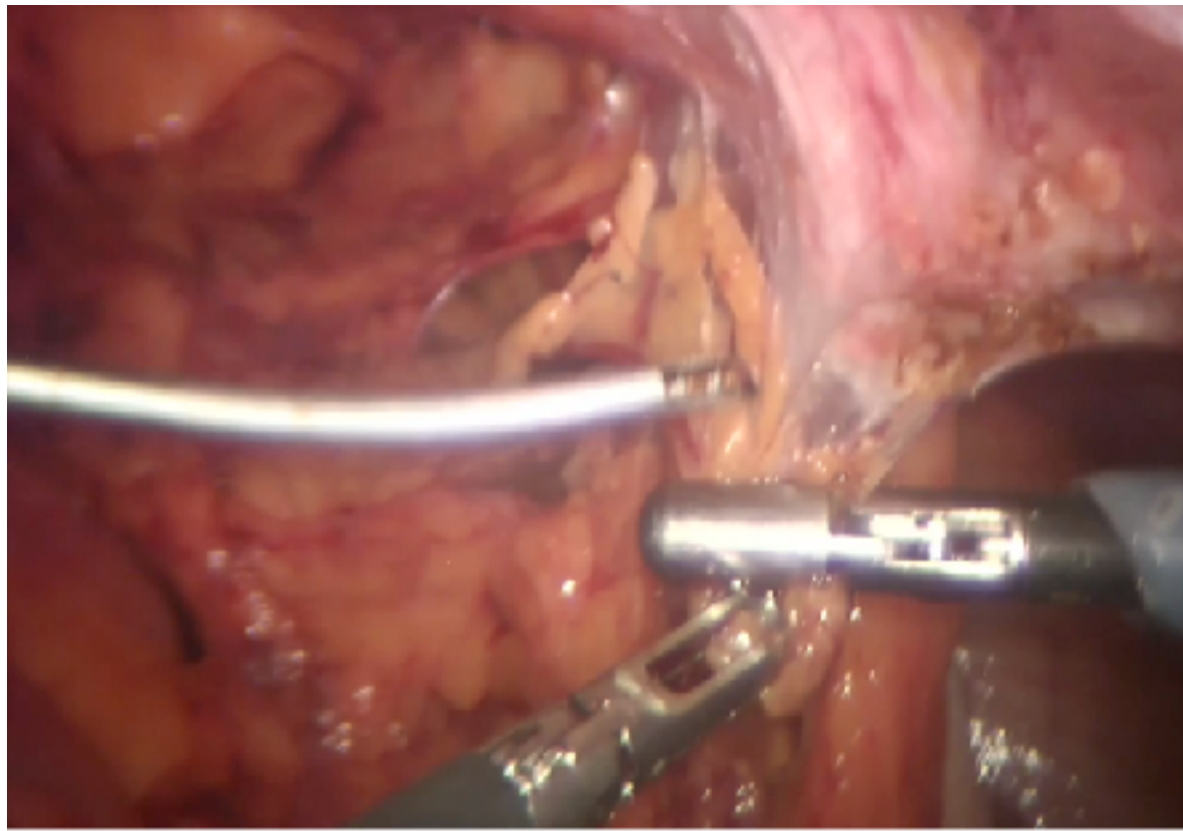


# Equipment

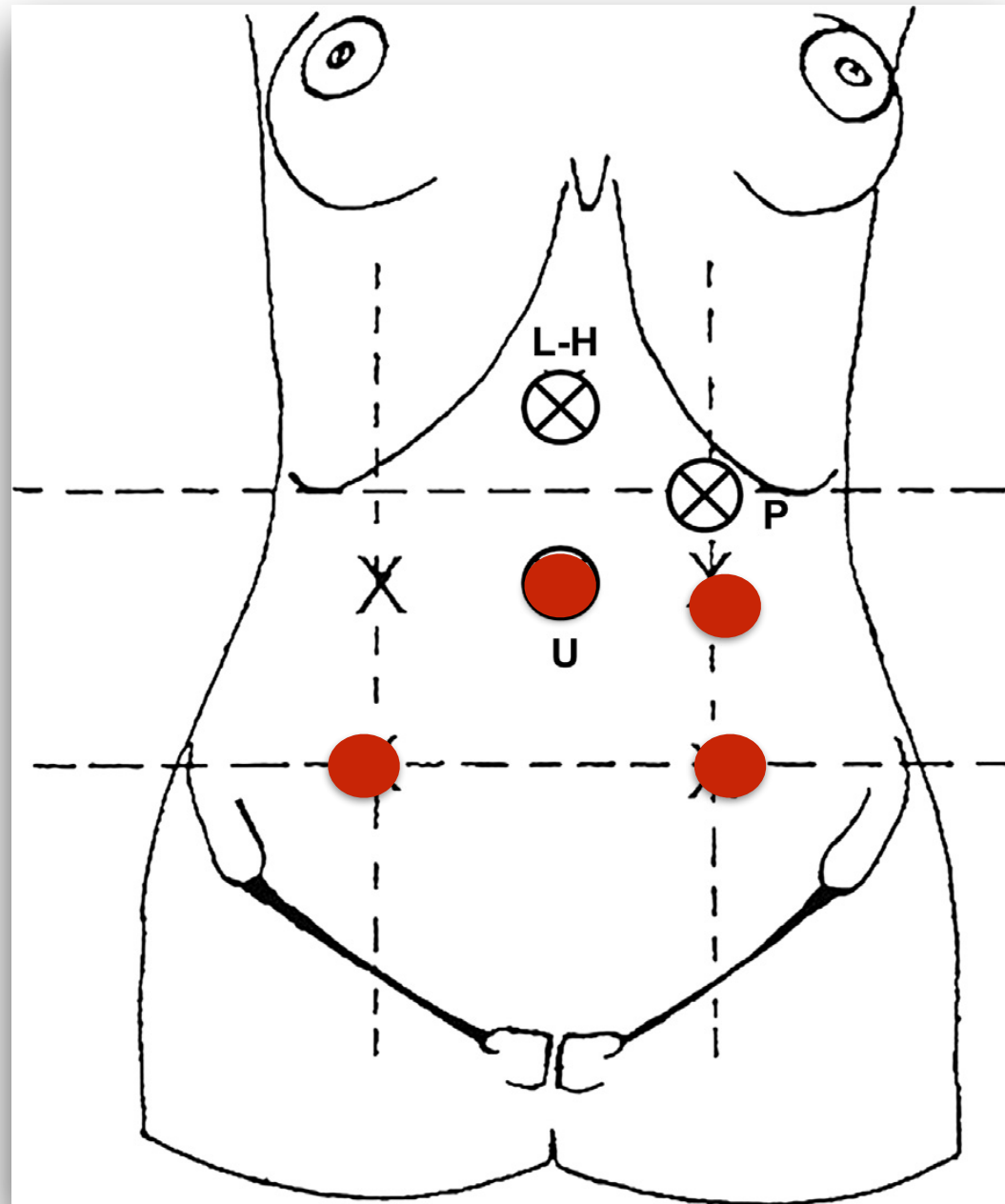




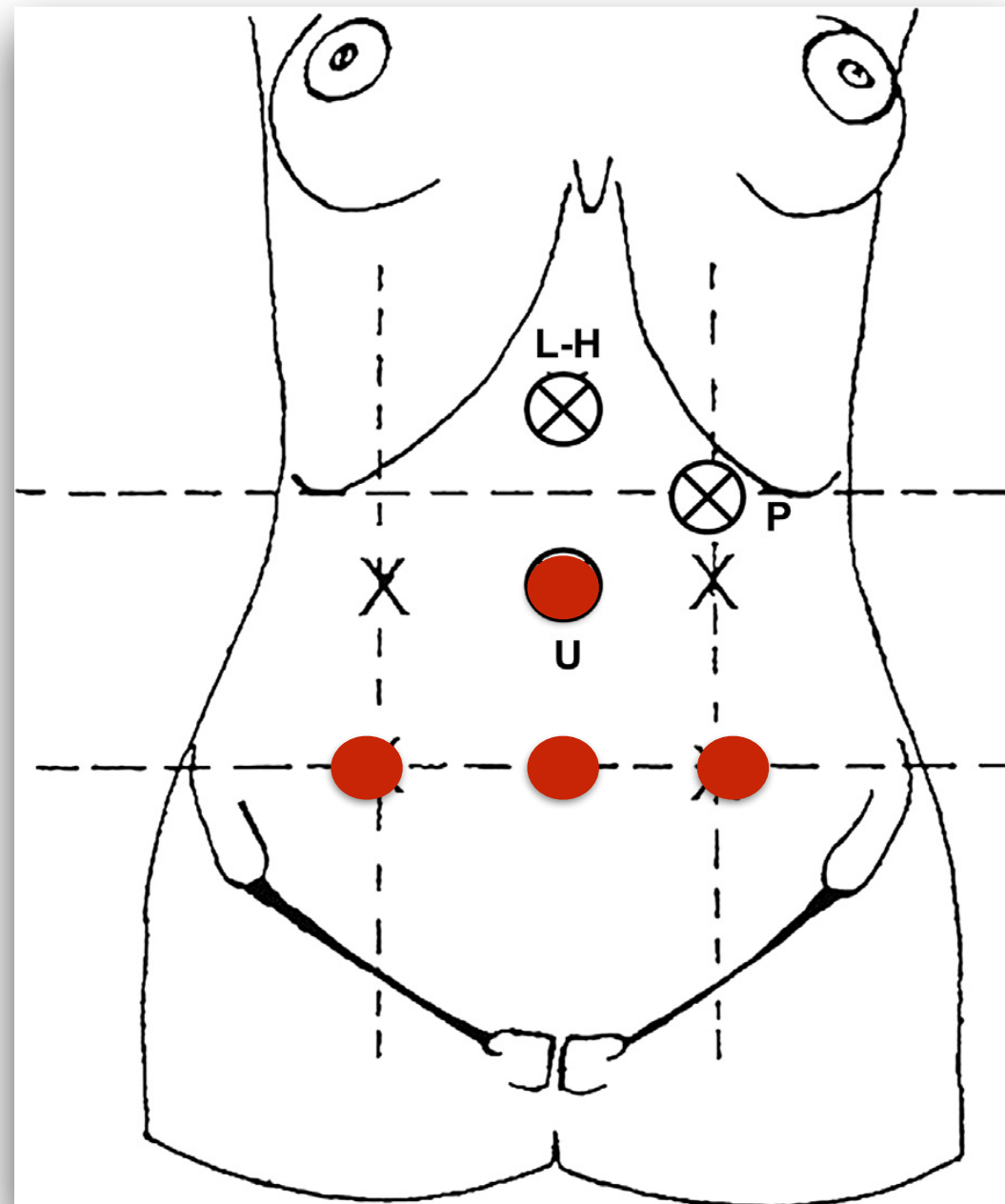
# *Laser (CO2, Diod vs), J-Plasma, Plasma Jet...*



# Port Placement



# Port Placement



# Surgical Technique

*The surgical treatment of endometriosis should aim at removing all visible areas of endometriosis....with margins free from disease as is the case in oncolologic surgery*

*(D.Redwine)*

- Removal of adhesions
- Restoration of normal pelvic anatomy
- Resection of endometrioma(s)
- Excision or ablation of endometriotic implants

# Tips for Dissection

- *“Follow the white line”*
- *“Traction – counter traction”*
- *“Follow the bubbles”*
- *“Apply divergent forces”*
- *“The fatty tissue is the friend of the surgeon”*



# Surgical Technique

## 1. Restoring the anatomy

Adhesiolysis

To drain ovarian Cysts

## 2. Exposure

Mobilisation the sigmoid

Organ Suspension (*Ovaries, Sigmoid, Uterus*)

Manipulator

## 3. Identification of the ureters

## 4. Dissection of pararectal spaces

## 5. Reevaluation of the lesions and Decision

# Surgical Technique

## 1. Restoring the anatomy

Adhesiolysis

To drain ovarian Cysts

## 2. Exposure

Mobilisation the sigmoid

Organ Suspension (*Ovaries, Sigmoid, Uterus*)

Manipulator

## 3. Identification of the ureters

## 4. Dissection of pararectal spaces

## 5. Reevaluation of the lesions and Decision






# 1. Restoring the anatomy

- Adhesiolysis

*“Follow the white line”*

- To drain ovarian Cysts



# 1. Restoring the anatomy

- Adhesiolysis

*“Follow the white line”*

- To drain ovarian Cysts



# Surgical Technique

1. Restoring the anatomy

Adhesiolysis

To drain ovarian Cysts

2. Exposure

Mobilisation the sigmoid

Organ Suspension (*Ovaries, Sigmoid, Uterus*)

Manipulator

3. Identification of the ureters

4. Dissection of pararectal spaces


5. Reevaluation of the lesions and Decision

## 2. Exposure

Mobilisation the sigmoid

Organ Suspension (*Ovaries, Sigmoid, Uterus*)

Manipulator





# Surgical Technique

## 1. Restoring the anatomy

Adhesiolysis

To drain ovarian Cysts

## 2. Exposure

Mobilisation the sigmoid

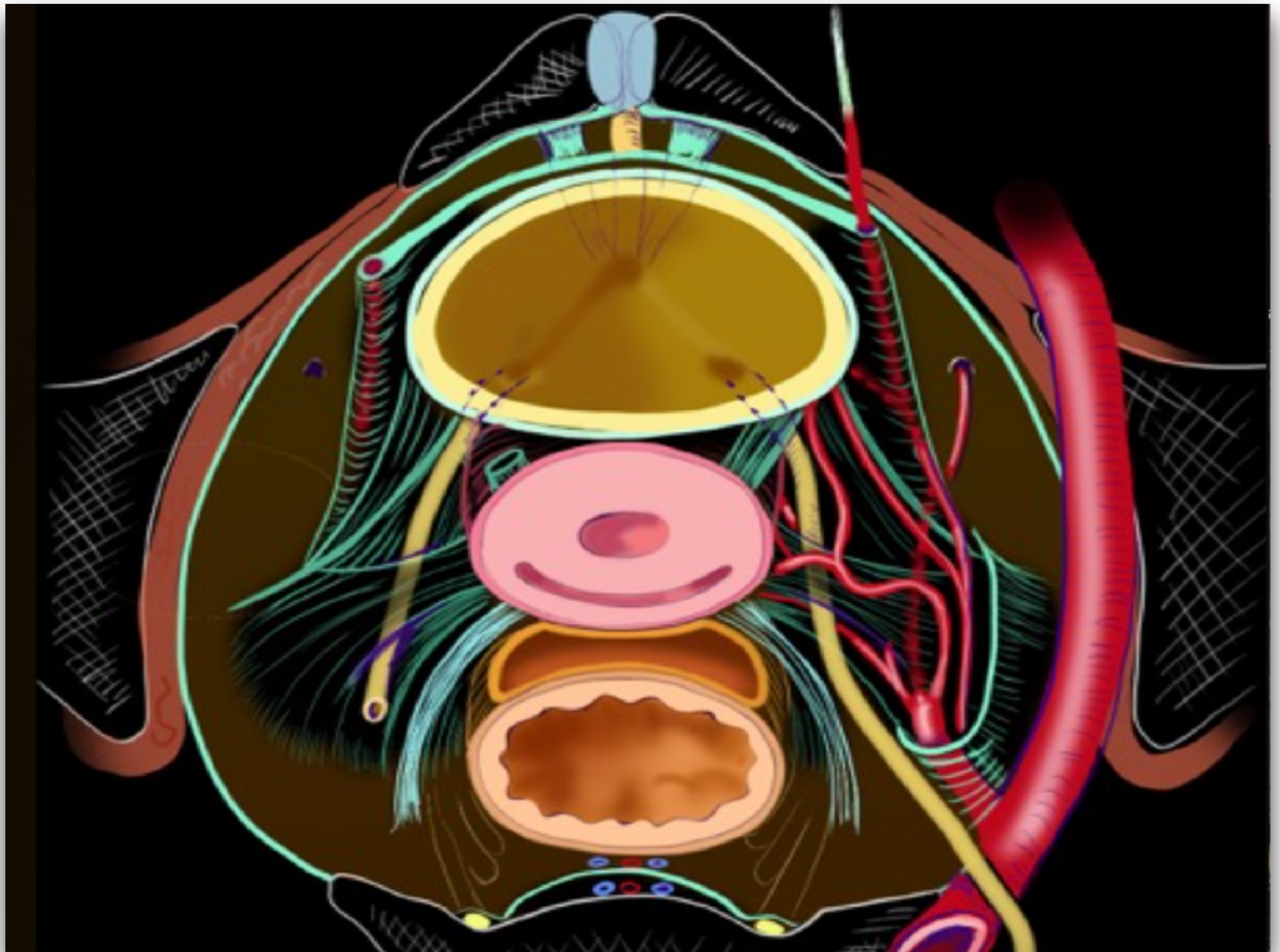
Organ Suspension (*Ovaries, Sigmoid, Uterus*)

Manipulator

## 3. Identification of the ureters



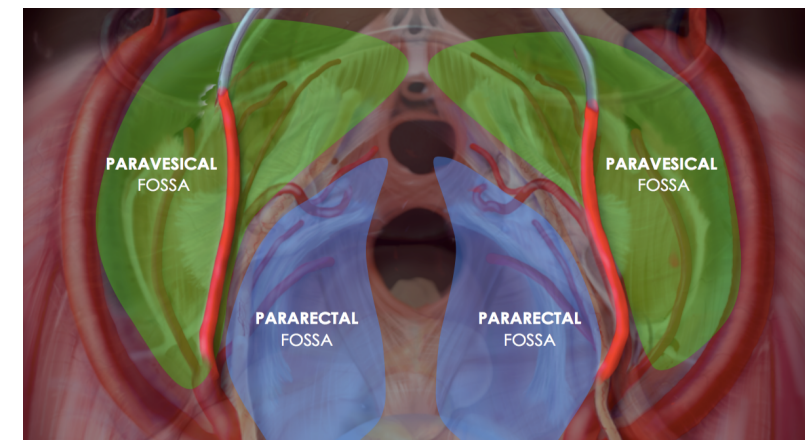
## 4. Dissection of pararectal spaces

## 5. Reevaluation of the lesions and Decision






3. Identification of the ureters
4. Dissection of pararectal spaces




# Endometrioma (Cystectomy) Surgical Technique


**1-Invagination Site**



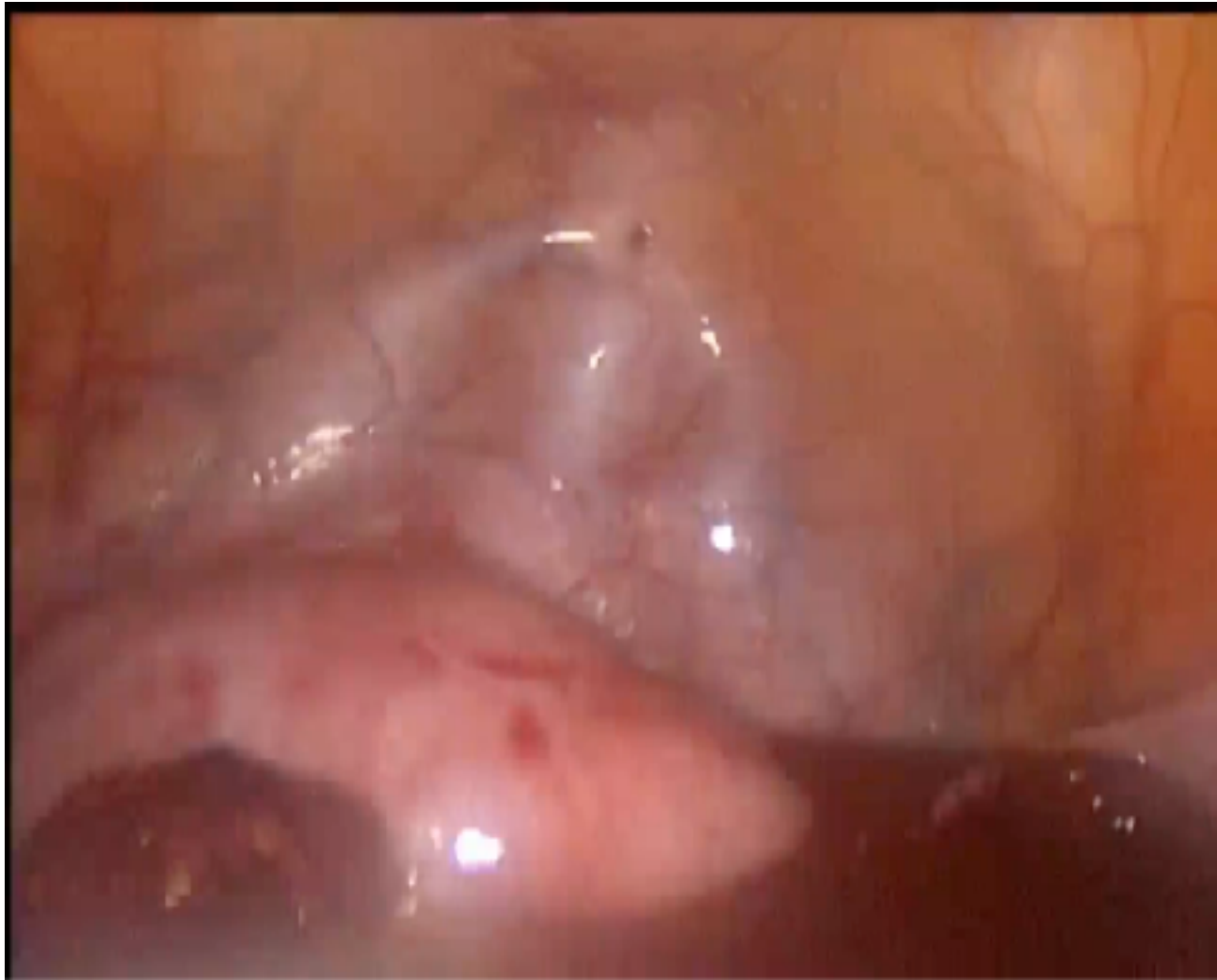
**2-Antimesenteric Site**



**3-Everted**

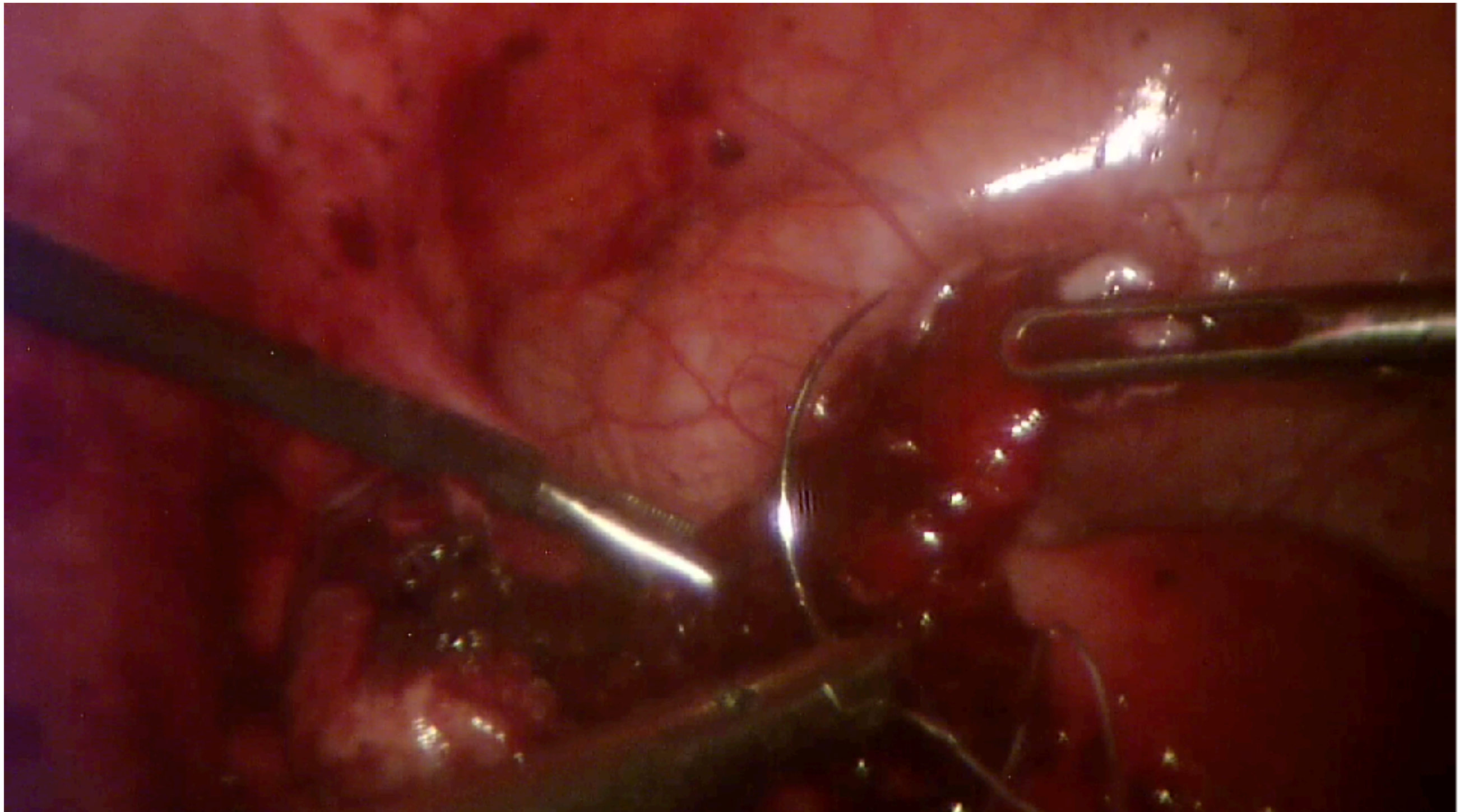


# Bleeding after cystectomy



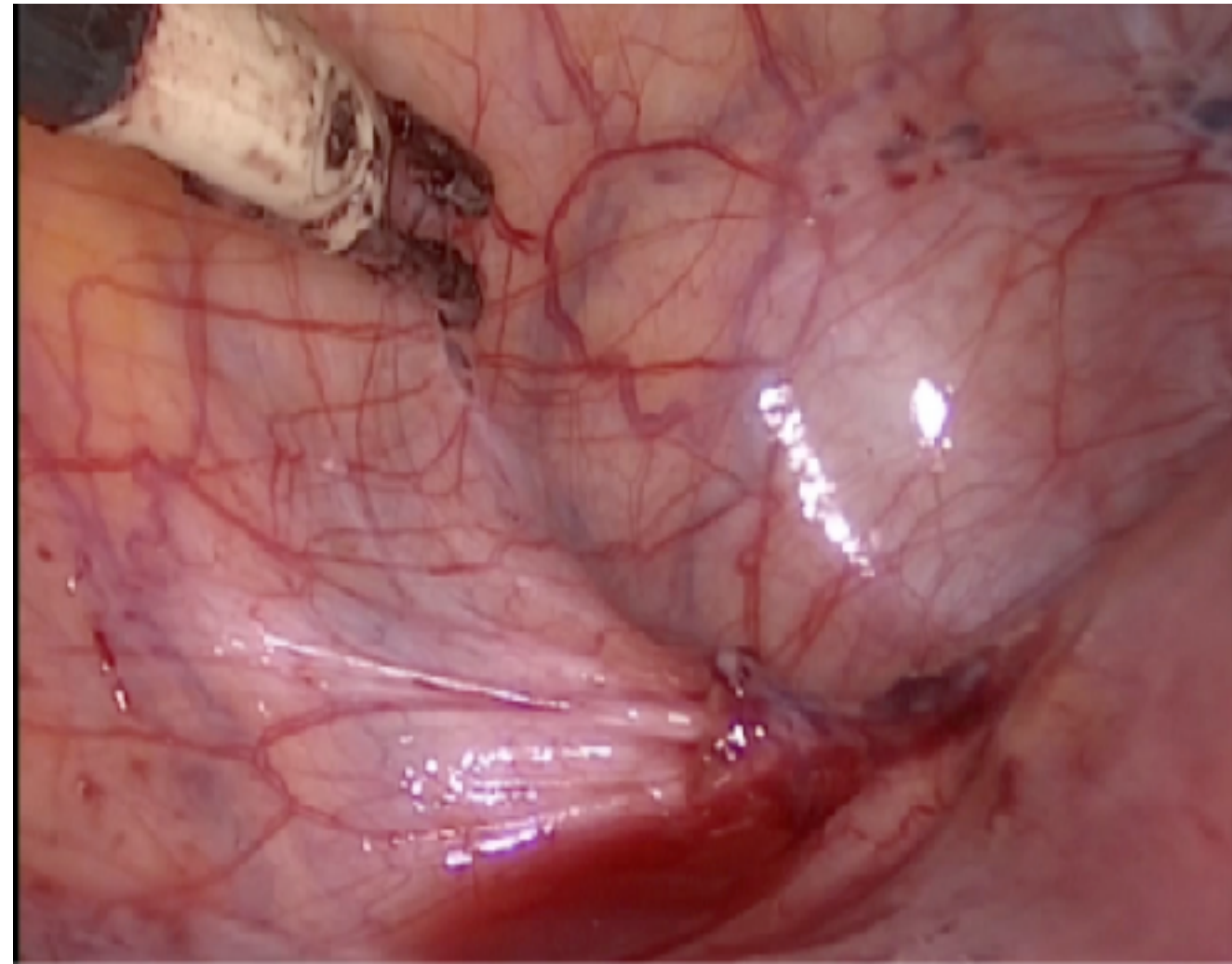
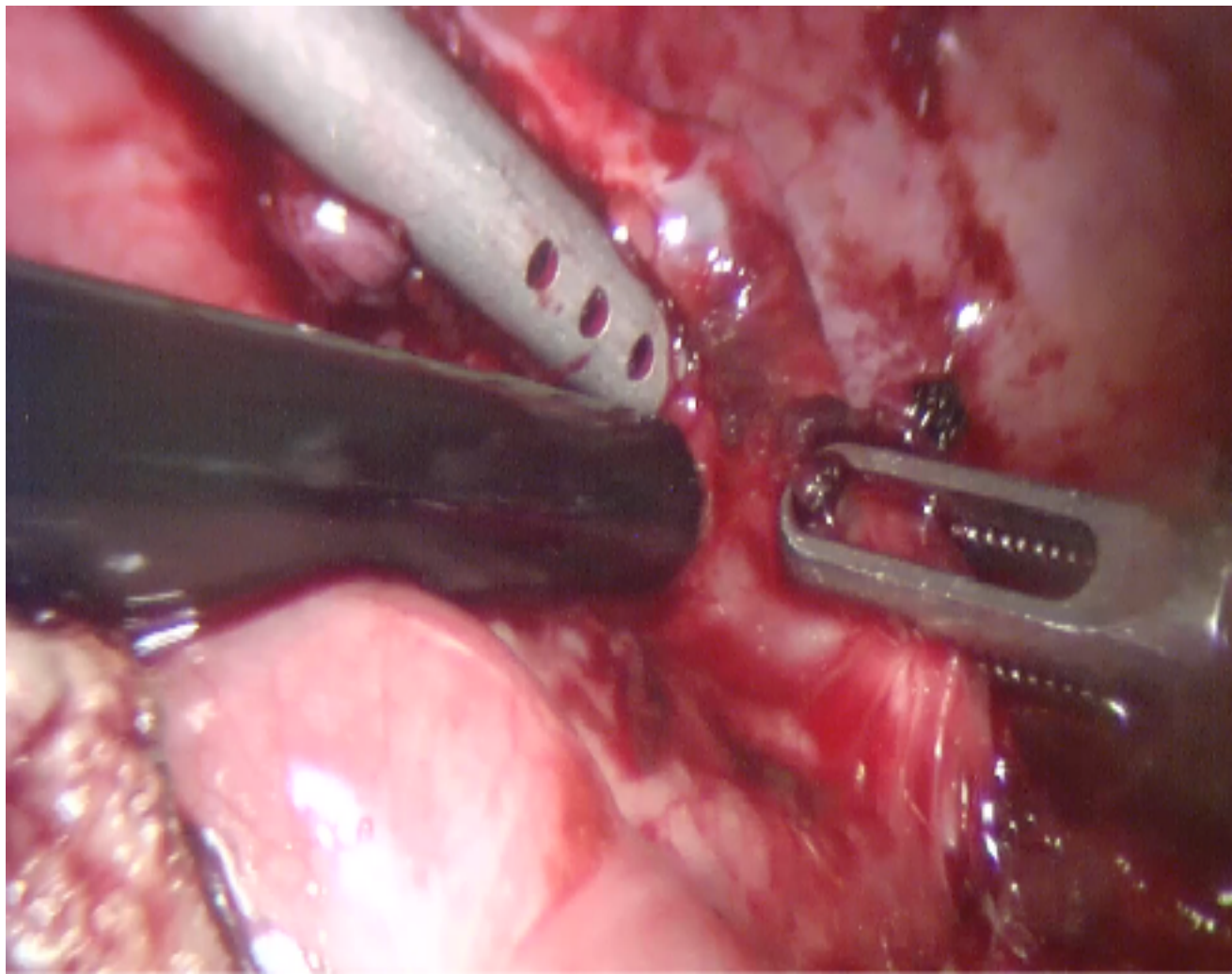


# Bleeding after cystectomy



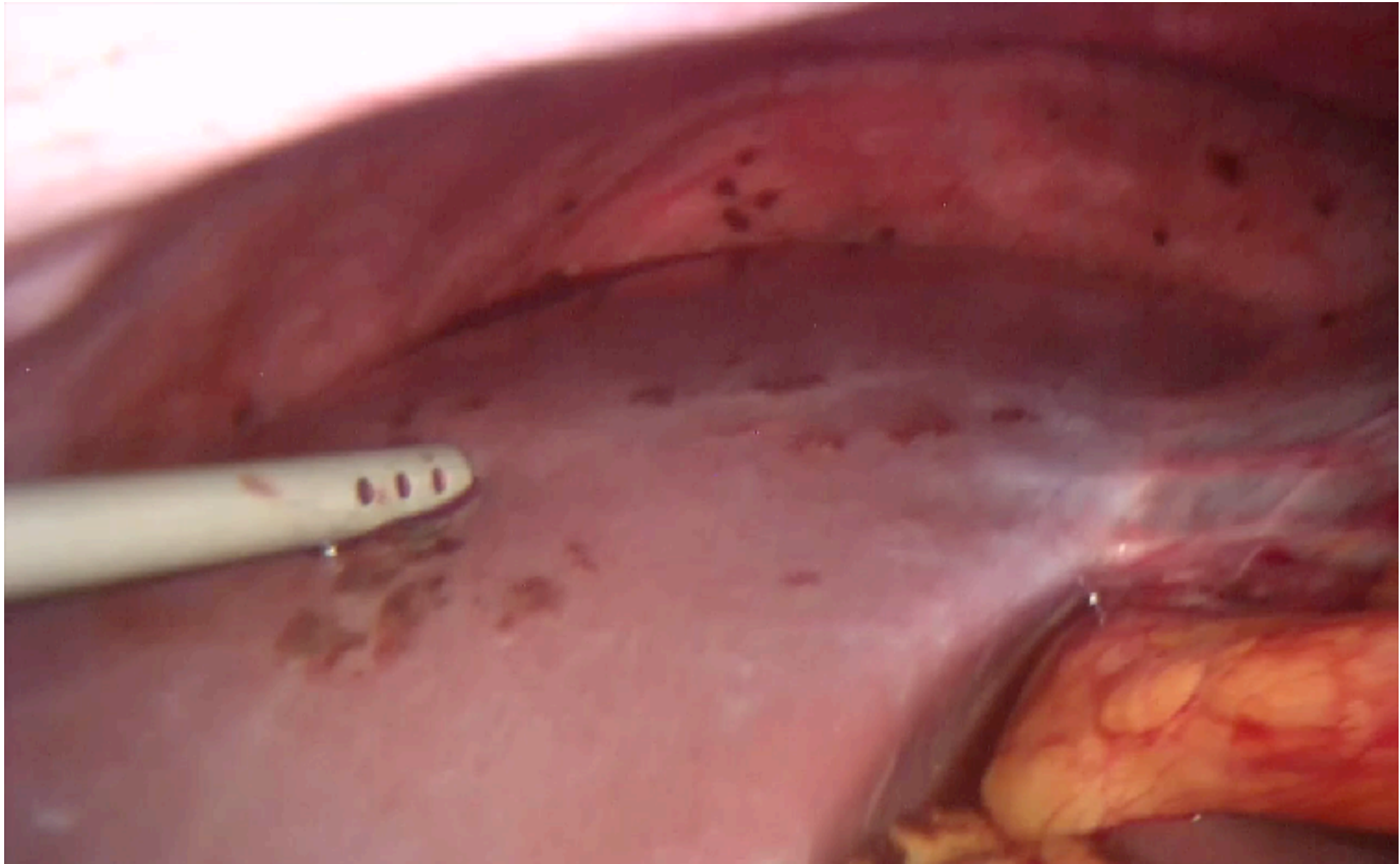


# Peritoneal Disease



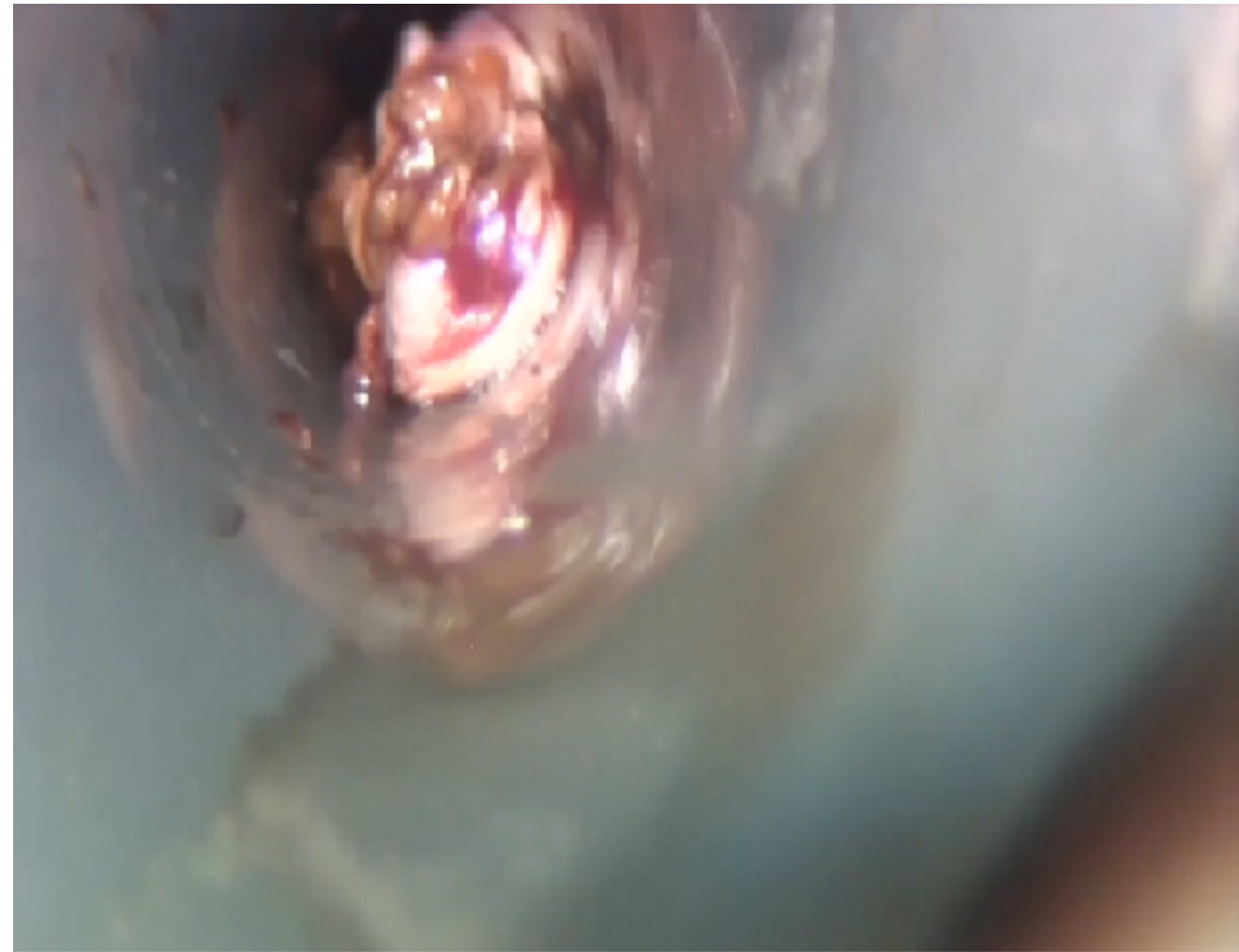
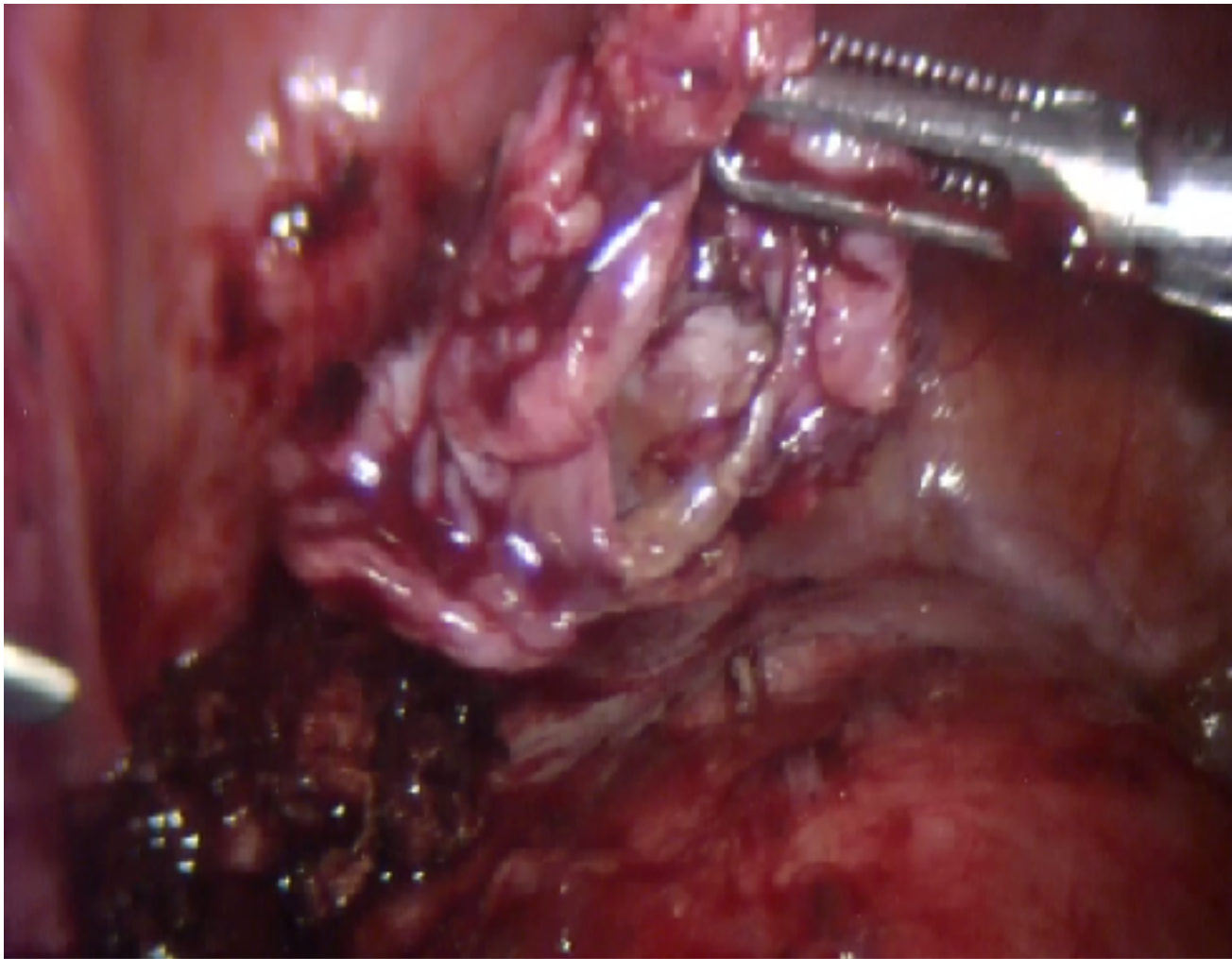
- Excise or Ablate?
- Which kind of energy sources?
- Mono, Bipolar, Laser?

# Diaphragmatic and Liver Endometriosis





# Tissue Extraction

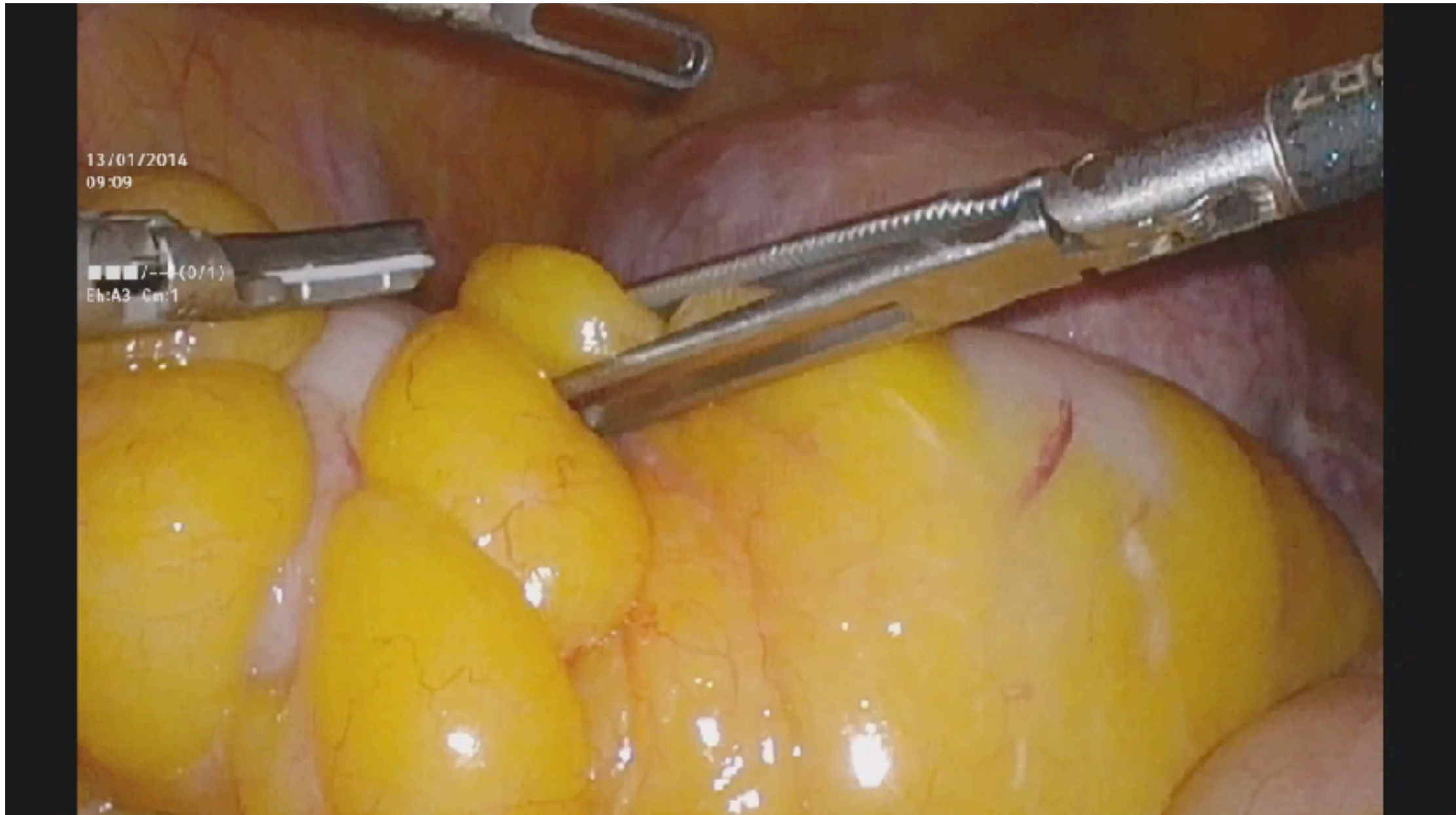


# Robotik Endometriozis Cerrahisi

# New Technologies




# Narrow Band Imaging (NBI)



# Fluorescence Imaging Technology

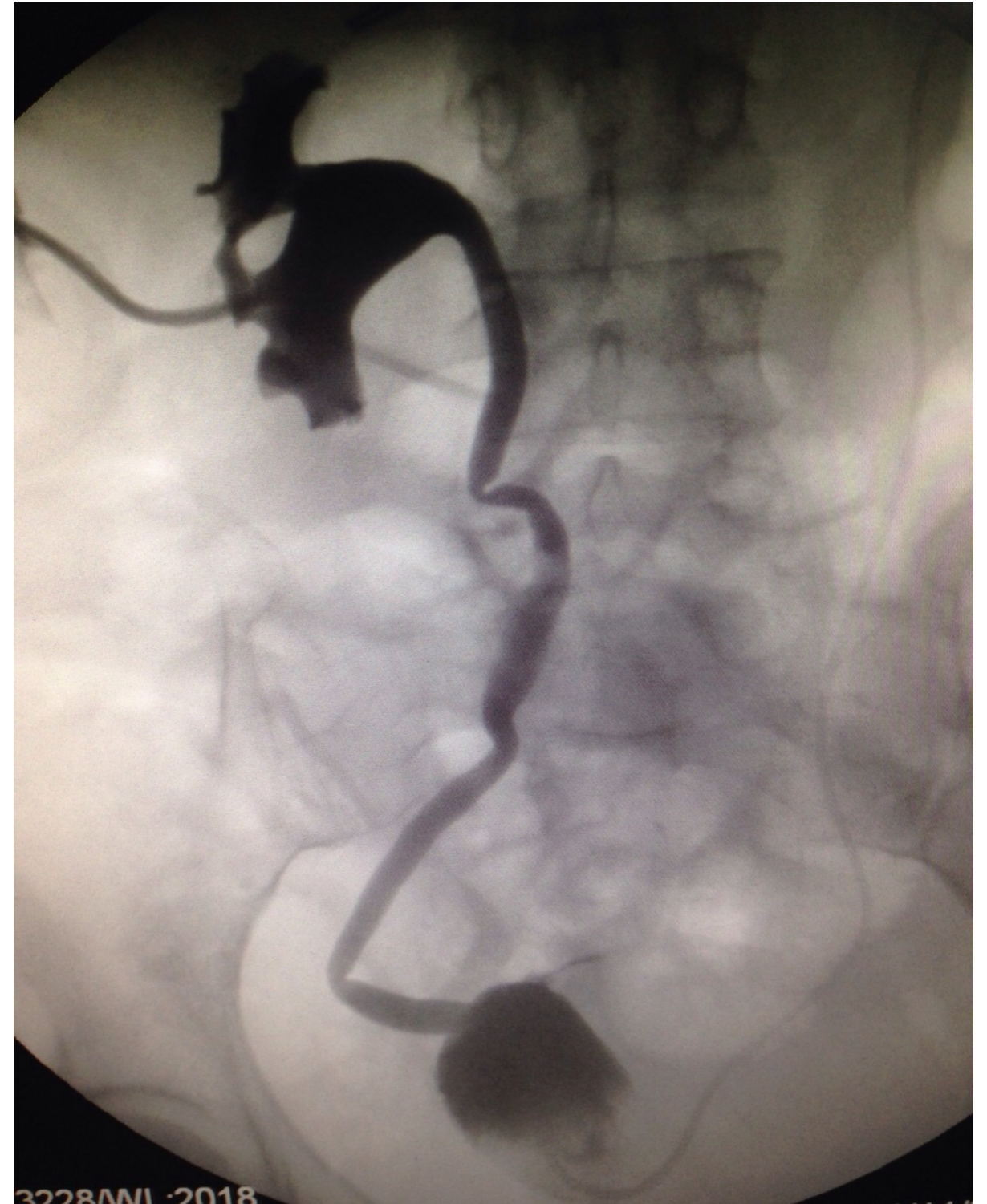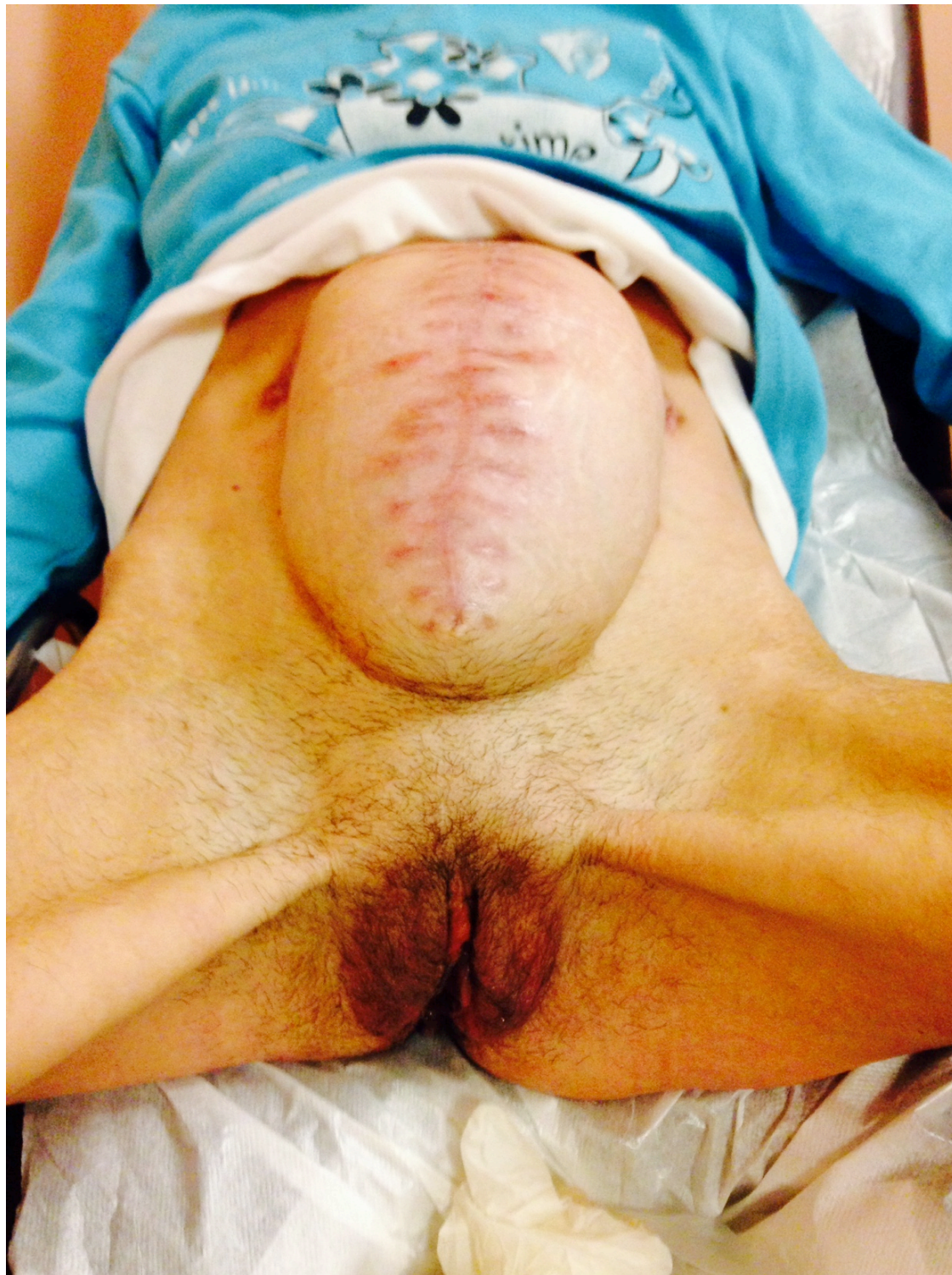## Indocyanine green (ICG)



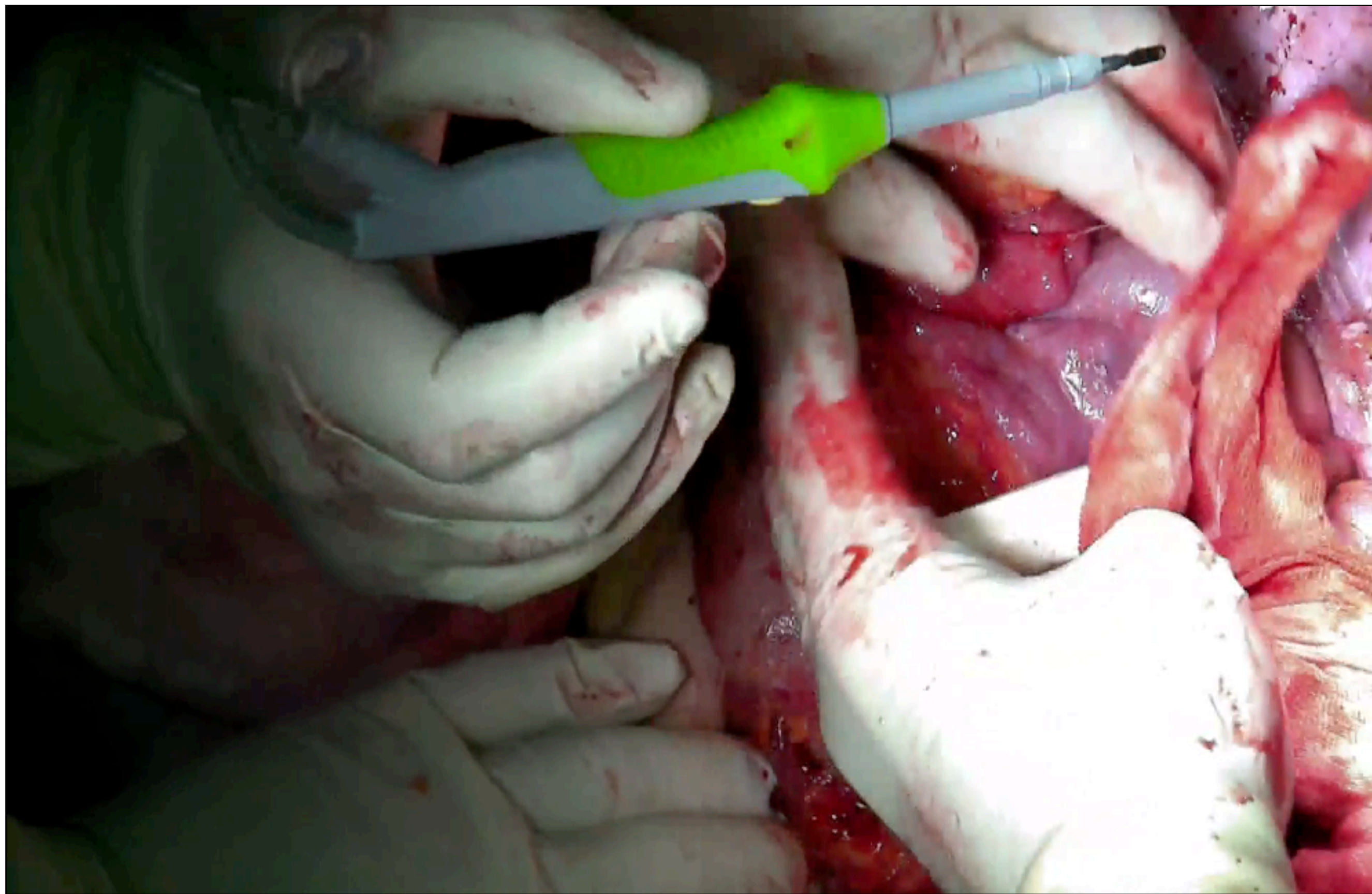


# Sometimes Something Goes Wrong!

- She could not walk without help
- The patient came with wheelchair







# Sonuç

- Endometriozis cerrahisinde standardizasyon oldukça sınırlıdır.
- Endometrioma ile ilgili diseksiyon ve enerji kullanımı ile ilgili cerrahların farkındalığı yeterli değildir.
- Ameliyat öncesi detaylı değerlendirme ve bilgilendirme son derece önemlidir. Olasılıklar hasta ile mutlaka net paylaşılmalıdır.
- Cerrahinin radikalitesi arttıkça komplikasyon, tam olmayan cerrahi yapıldığında ise hastalıksız yaşam nerdeyse imkansız hale gelmektedir.



# Sonuç

Ciftin  
Önceliđi

Yas,  
Yumurtalık  
Kapasitesi

Medikal Tedavi

Cocuk İsteđi?

Ađrı &  
Yaşam Kalitesi

Süpheli Görüntü

Cerrahi



# 1<sup>st</sup> Istanbul Chronic Pelvic Pain Symposium

April 20<sup>th</sup> - 21<sup>st</sup>, 2018

Acibadem Altunizade Hospital  
Istanbul / Turkey



[www.endometriosisiturkey.com](http://www.endometriosisiturkey.com)

'What we know, What we don't know!'

**Symposium Chairs:** Taner Usta, Gül Köknel Talu, Michael Hibner, Ahmet Kale

## Invited International Faculty



Michael  
Hibner  
USA



Horace  
Roman  
FR



Alysson  
Zanatta  
BR



Vito  
Chiantera  
IT



Paolo  
Vercellini  
IT



Gökhan  
Kiliç  
USA

Supported by:



**LIVE** Live  
Surgery

Date : April 20<sup>th</sup>, 2018  
Starts at : 12:10  
Duration : 2 hours  
Surgeon : Horace Roman  
Case : Deep Endometriosis with Sacral Nerves Roots  
Center : Rouen University Hospital, Rouen, France

Contact e-mails: [rkinay@opteamist.com](mailto:rkinay@opteamist.com), [tolgakaracan84@gmail.com](mailto:tolgakaracan84@gmail.com)

# Cerrahi Teknik

- Pelvik anatomisinin ortaya konması
- Hastalığın yaygınlığının belirlenmesi
- Endometrial odaklar ablasyon veya eksizyon?
- Endometrioma tam eksize edilir
- Oblitere Douglas serbestleştirilir
- Rektovaginal nodül çıkarılır

# Standardizasyon mümkün mü?





